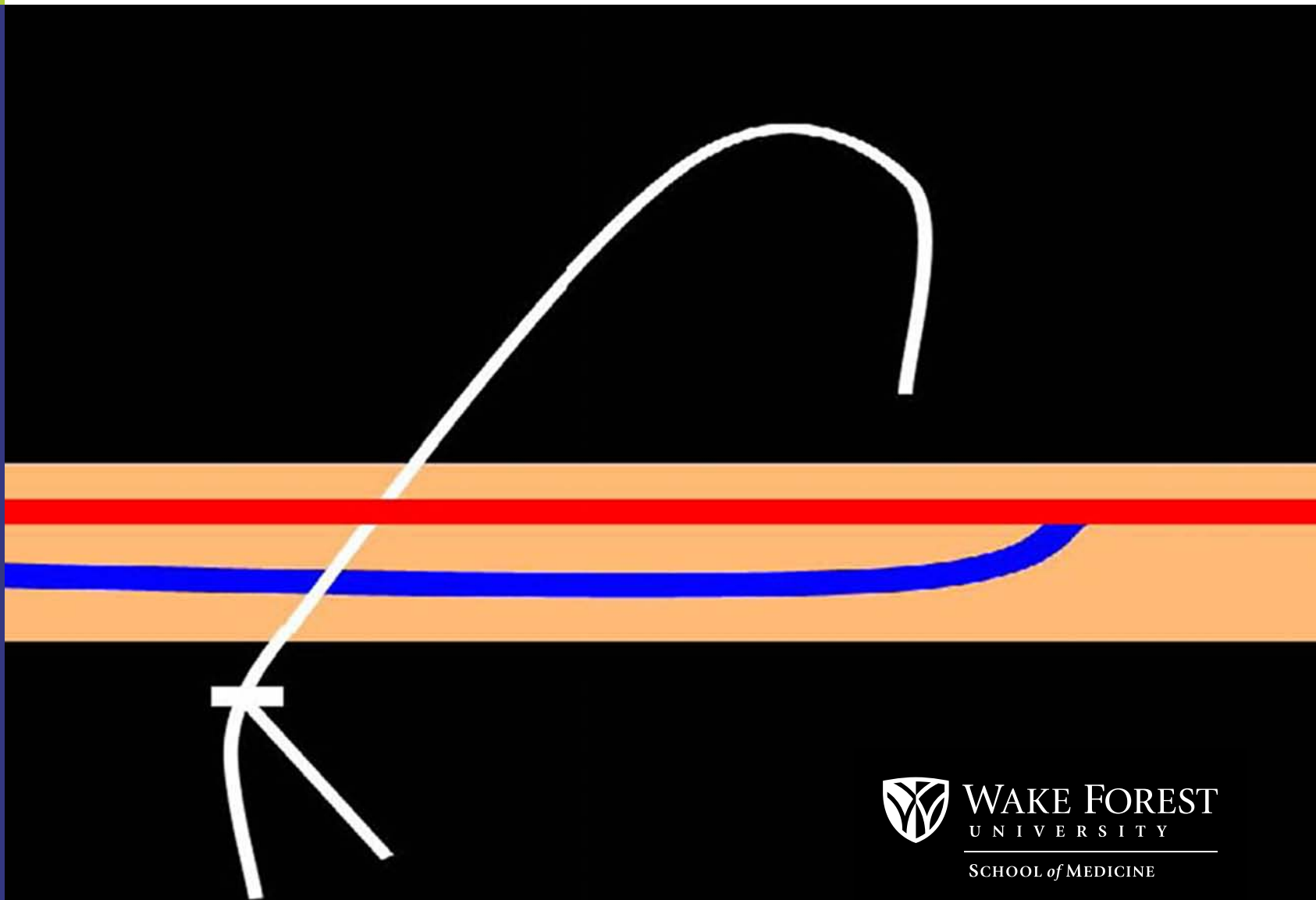



Atlas of Dialysis Vascular Access

Tushar J. Vachharajani, MD, FASN, FACP



Dedicated to all dialysis patients and hard-working staff



Cover design – Vipul Vachharajani
Schematic representation
of arteriovenous fistula
overlapped by a tunneled
central venous catheter

Editorial Assistance–Amanda Goode, MA
Research Programs Development Manager
Department of Internal Medicine
Wake Forest University School of Medicine

Medical Illustration and atlas production
Creative Communications
Wake Forest University School of Medicine
www.wfubmc.edu/creative

© 2010 by Tushar J. Vachharajani. All rights reserved



ATLAS OF DIALYSIS VASCULAR ACCESS

TABLE OF CONTENTS

<i>Anatomy of Dialysis Vascular Access</i>	1
<i>Tunneled Catheters</i>	13
<i>Arteriovenous Fistulas</i>	28
<i>Arteriovenous Grafts</i>	53
<i>Glossary</i>	67
<i>Bibliography</i>	68

FOREWORD

The old adage “a picture is worth a thousand words” is certainly exemplified by Tushar Vachharajani’s *Atlas of Dialysis Vascular Access*. The Atlas provides a rich source of pictorial information presented in a simple, straightforward fashion that will have value for the entire patient care team, including physicians, nurses, patient care technicians, dieticians and social workers.

Jack Work, MD

Past President

American Society of Diagnostic and Interventional Nephrology (ASDIN)

PREFACE

I have a passion for improving the basic understanding of the dialysis vascular access. A patient's survival depends on proper functioning of this lifeline, yet the dialysis vascular access remains the Achilles' heel for hemodialysis patients. Unfortunately, because of the myriad medical problems faced by a patient with renal failure, the dialysis access gets the least amount of attention.

The current practice of dialysis treatment in the United States depends heavily on an ancillary staff remotely supervised by a nephrologist. The training curriculum for physicians provides minimal cross-training in different specialties involved in the creation and maintenance of a dialysis vascular access. Moreover, the ancillary staffs that provide and supervise the bulk of the care are inadequately trained in the proper handling of the vascular access.

Diagnostic accuracy and active and timely intervention depend heavily on visual clues that are frequently missed. There is a need to improve the understanding and visual skills related to the vascular access. The Atlas of Dialysis Vascular Access is a sincere effort in pursuit of this goal. "A picture is worth a thousand words"—a common adage that can be aptly used to describe this bedside tool for education. Images express a concept faster and with greater impact than do pages of textbooks or hours of lectures. This atlas highlights the basic anatomy of the most frequently used vascular accesses and their associated problems. The images have been collected from patients who have endured the problems and have graciously consented to be photographed.

The primary intended audiences for the atlas are physicians involved in dialysis vascular access management, physician extenders, dialysis nurses, patient care technicians, medical students and residents, and clinical educators involved in training the future generation of dialysis care providers. I hope that this atlas will ultimately lead towards improved quality of vascular access care.

I would like to thank the Dialysis Access Group of Wake Forest University School of Medicine (www.dagwfu.com) and its staff (Jean Jordan, RN, Tina Kaufman, RN, Sherry Crawford, RN, Leann Hooker, RN, Wendy Mundy, LPN, Joyce Jackson, PCT, Margaret Bordner, RT-R and Andrea Roark, RT-R) for their assistance with this project. I am grateful to Health Systems Management, Inc. for providing me with the basic resources needed to collect the pictures. And lastly, I would like to thank my son, Vipul Vachharajani, who spent his valuable high school vacation time to help me with the cover design and with the atlas layout.

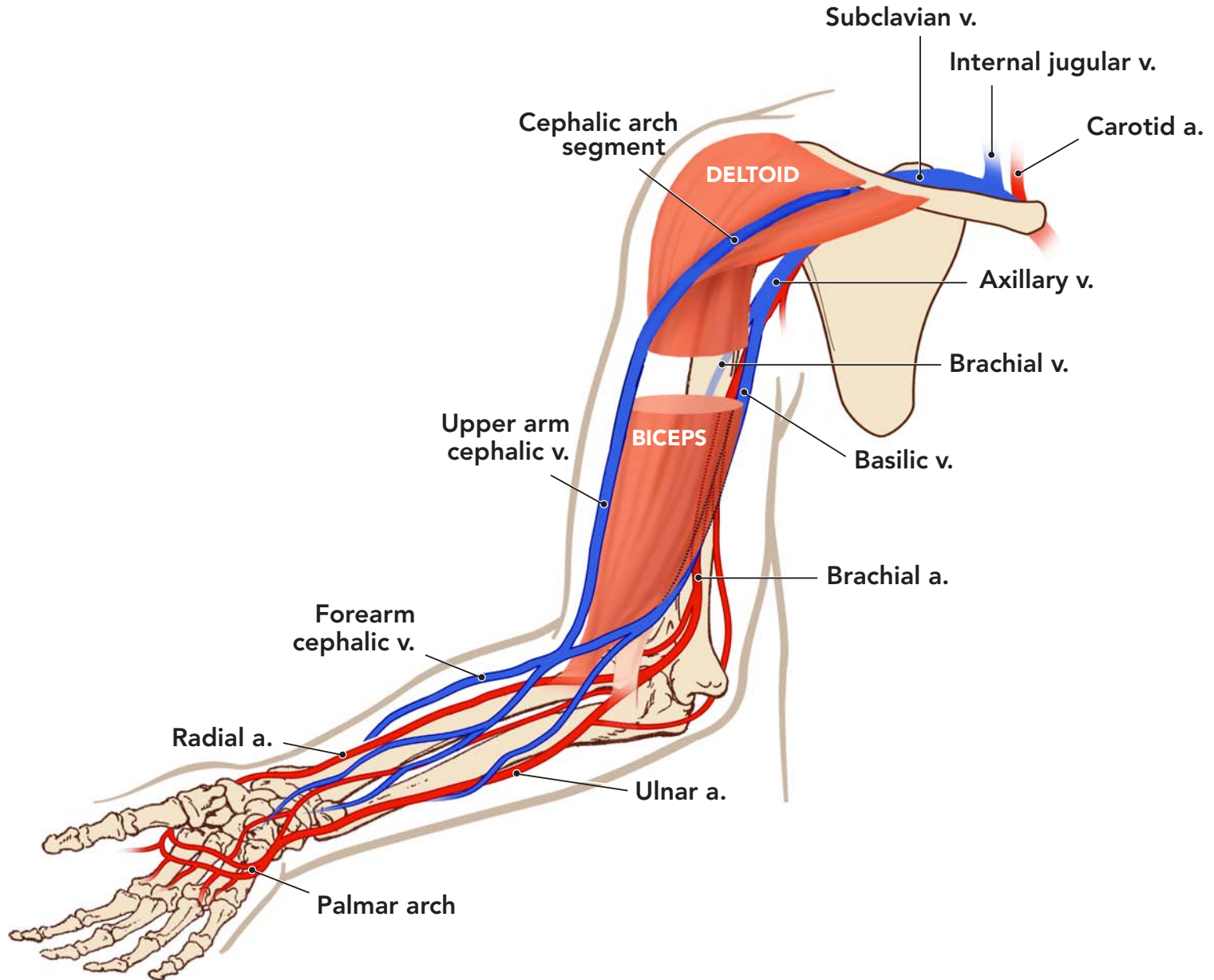
Tushar J. Vachharajani, MD, FACP, FASN

Dialysis Access Group of Wake Forest University School of Medicine

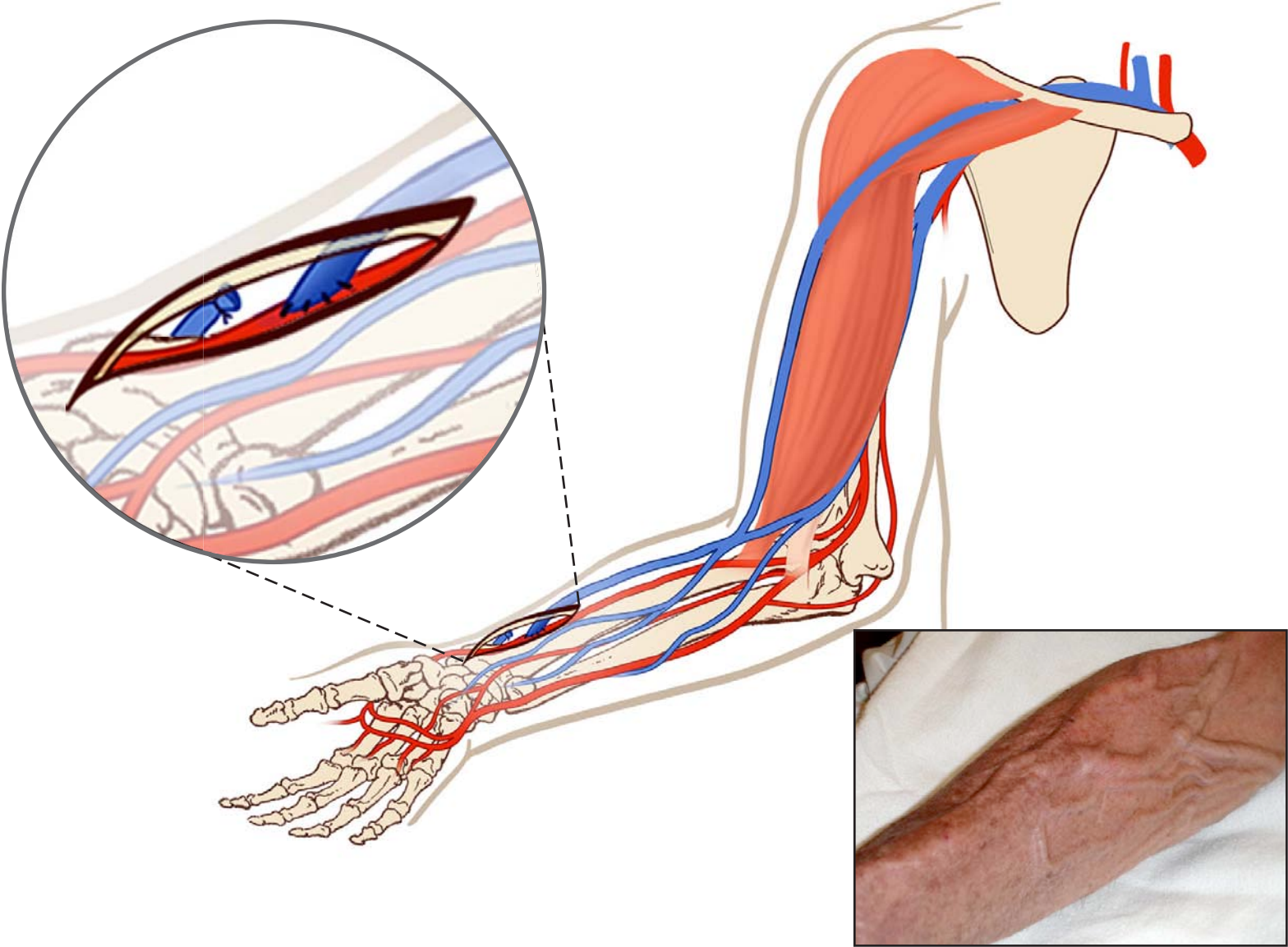
ANATOMY OF DIALYSIS VASCULAR ACCESS

- A basic understanding of the anatomy of vessels utilized to create the vascular access is crucial for proper handling and care of an access during dialysis therapy.
- The venous system of an extremity includes superficial and deep veins. The superficial system is most important for access creation.
- The superficial vein in the upper extremity that is preferred and most commonly utilized for arteriovenous fistula creation is the cephalic vein.
- The radiocephalic arteriovenous fistula at the wrist is the first choice hemodialysis access and utilizes the forearm segment of the cephalic vein.
- The brachiocephalic fistula at the elbow utilizes the upper arm segment of the cephalic vein and generally is the second choice site for arteriovenous fistula creation.
- The other superficial veins in the forearm (the basilic vein on the ulnar side and the median basilic vein near the elbow) are occasionally used for arteriovenous fistula creation.
- The deep veins in the forearm are not ideal for arteriovenous fistula creation. The deep veins in the upper arm are the brachial and basilic veins that run parallel to the brachial artery.
- The basilic vein in the medial aspect of the upper arm is the most common deep vein utilized for arteriovenous fistula creation. The basilic vein is mobilized from its usual location and transposed superficially through the deep fascia in the upper arm to create the “transposed basilic vein” arteriovenous fistula.
- The brachial veins in the upper arm are used for dialysis access as a last resort. The brachial veins and the basilic vein join and continue as the axillary vein until the outer border of the first rib. The axillary vein continues as subclavian vein from the outer border of the first rib and extends to the sternal end of the clavicle.
- A graft made from synthetic material like polytetrafluoroethylene (PTFE) is utilized for dialysis access creation if the native vessels are not suitable for creating an arteriovenous fistula. The forearm loop, upper arm straight and thigh loop grafts are commonly utilized configurations for creating a dialysis access.

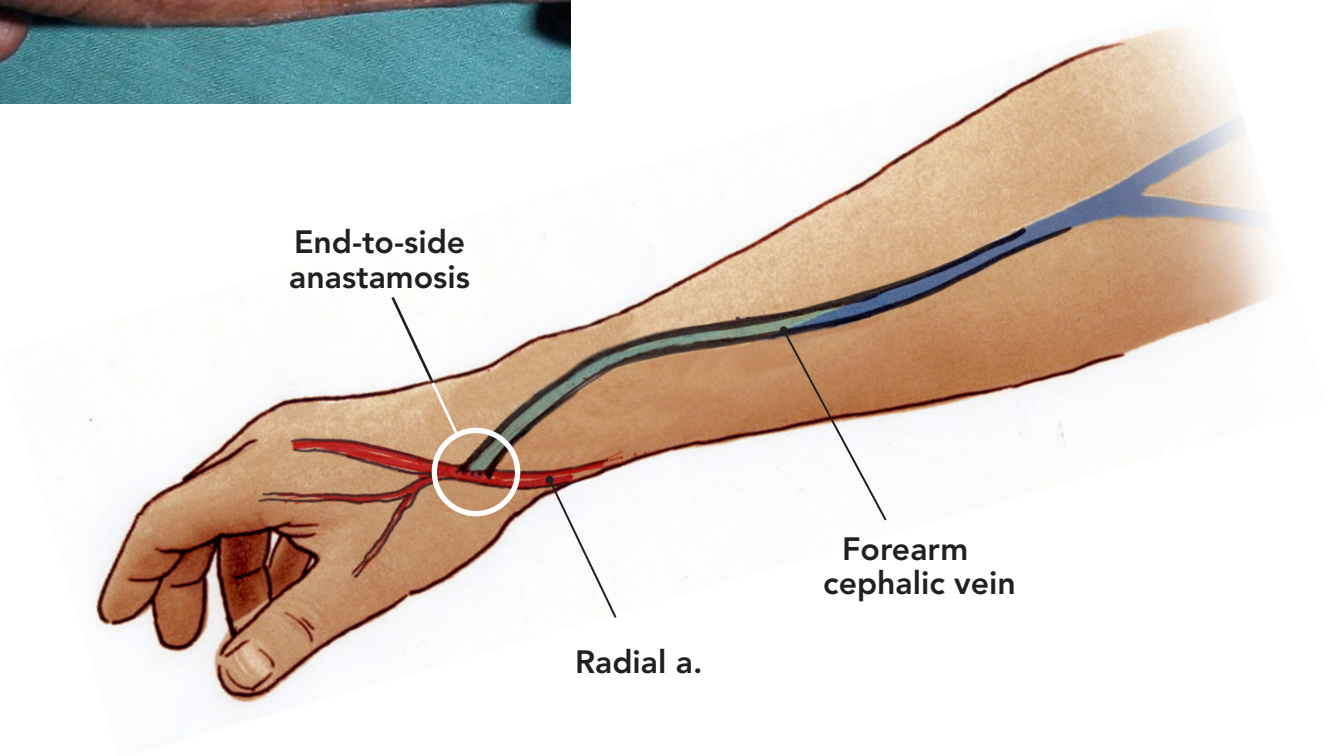
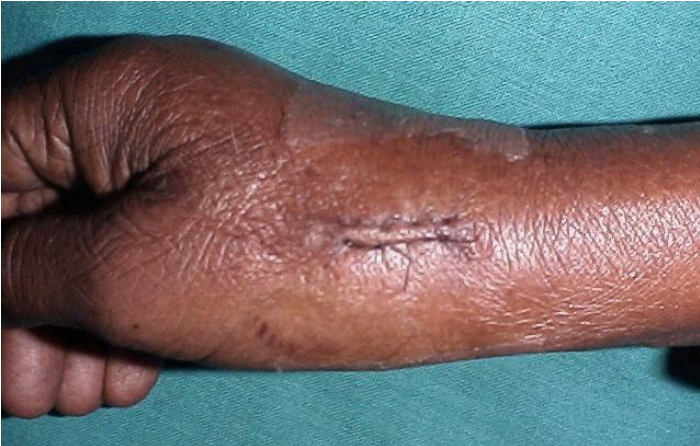Anatomy of Upper Extremity Vessels



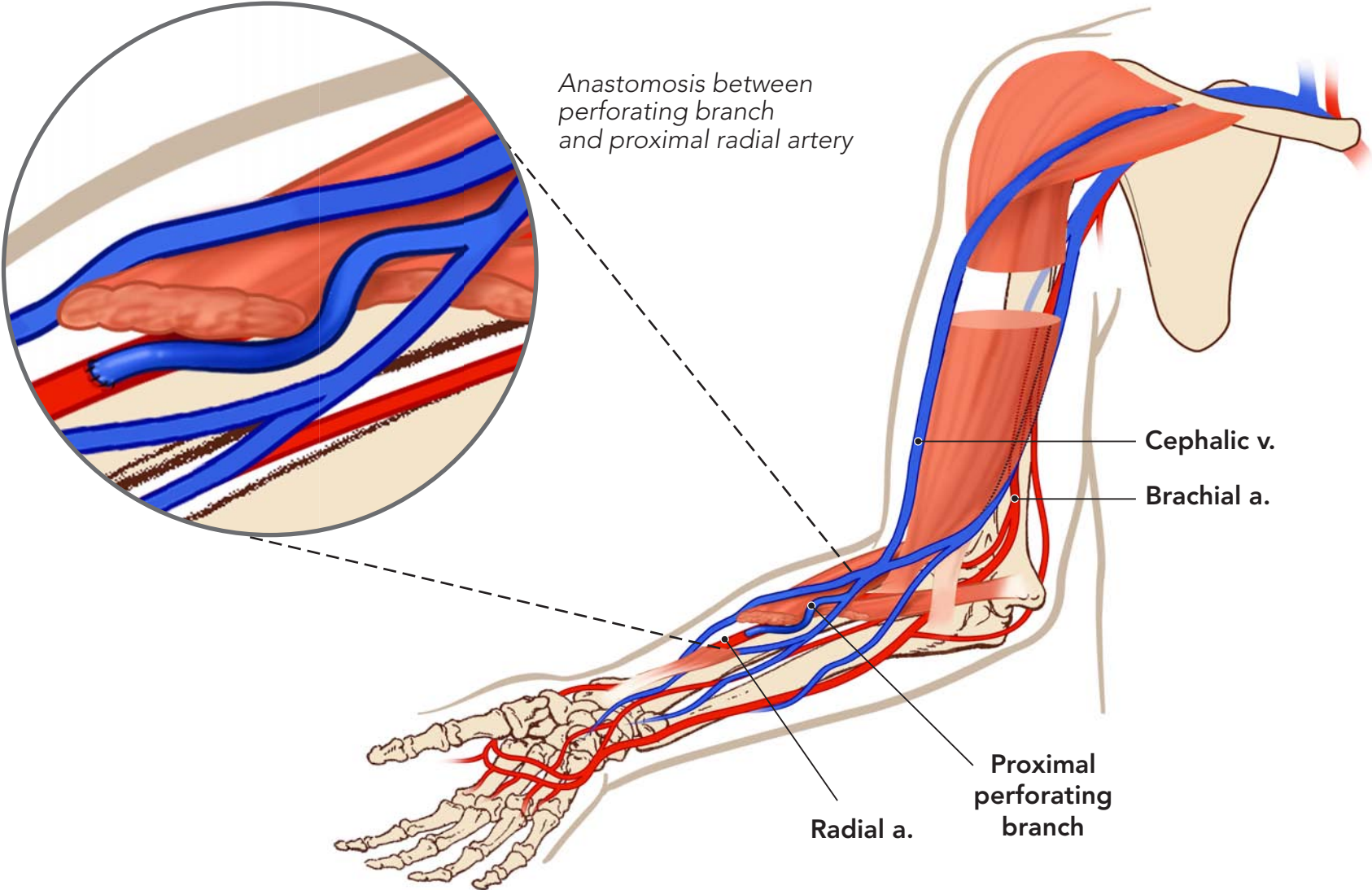
Radiocephalic Arteriovenous Fistula (Brescia-Cimino)



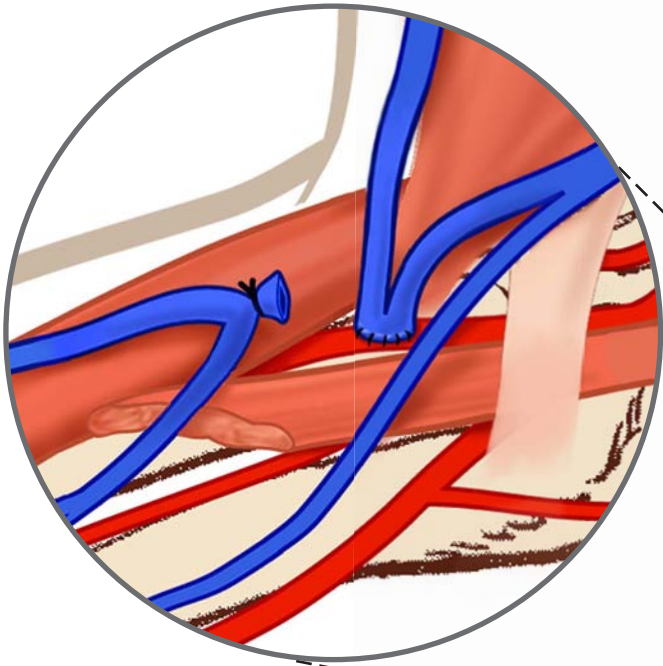
Snuff-box Arteriovenous Fistula



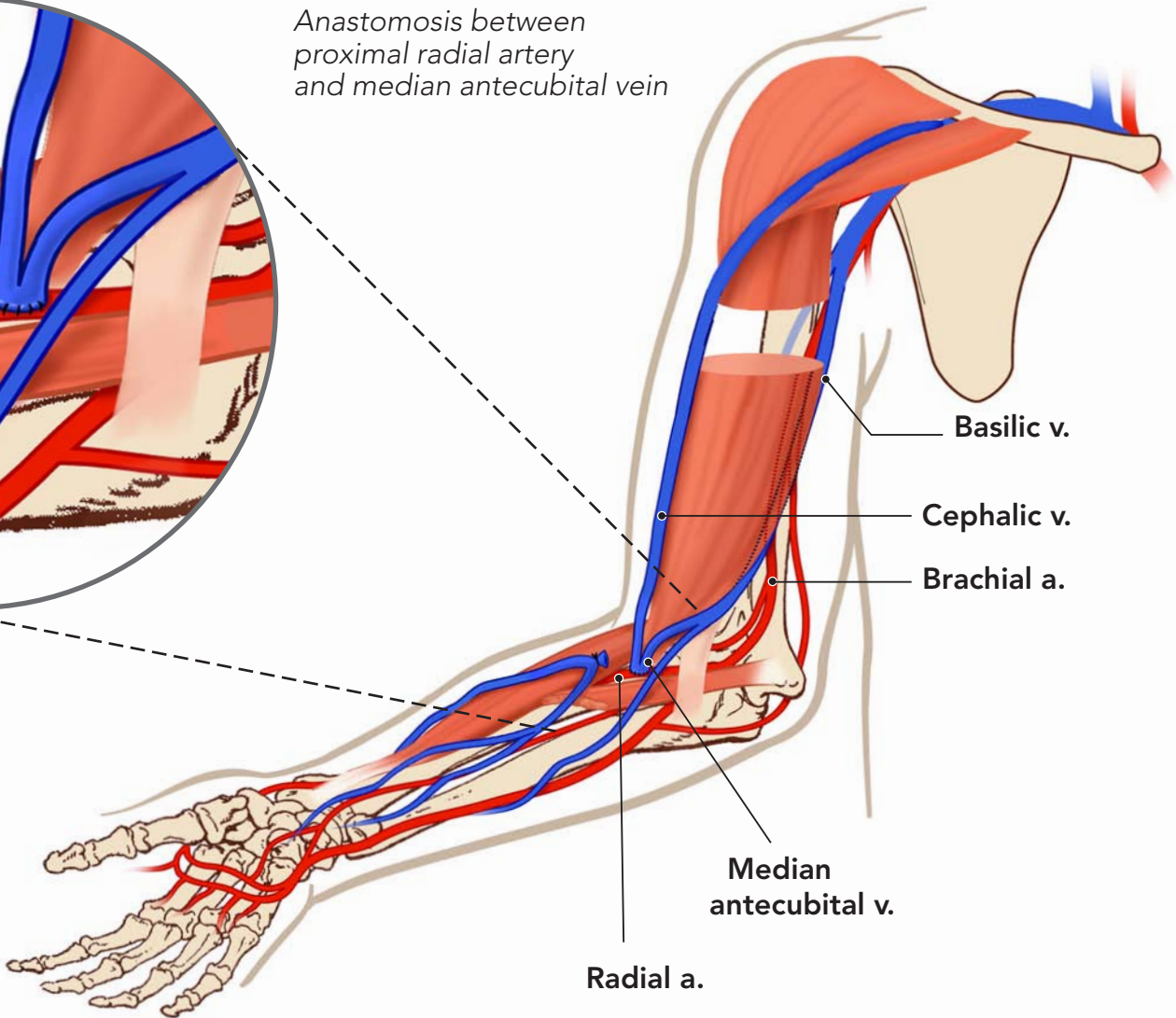
Proximal Forearm Arteriovenous Fistula



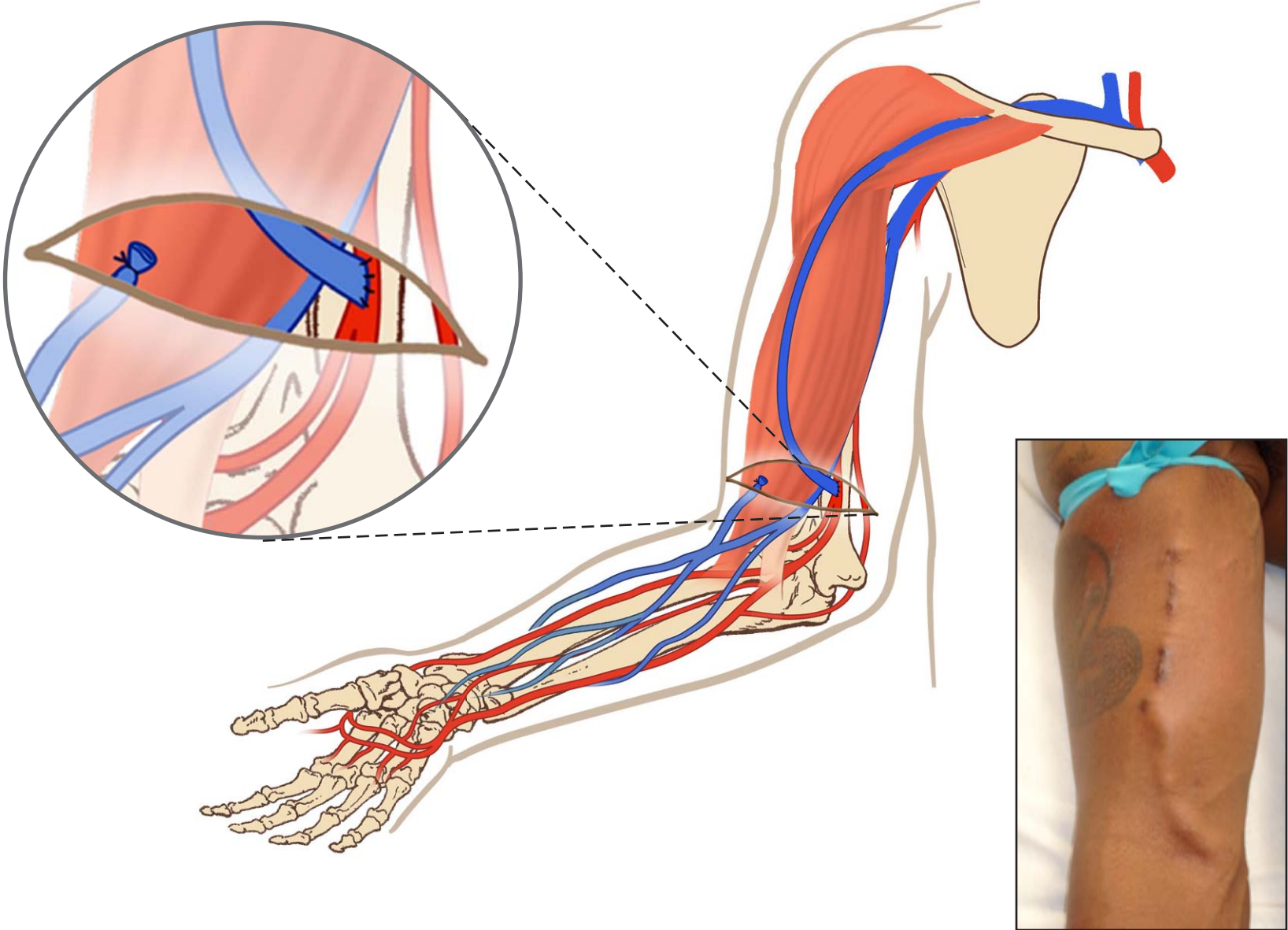
Proximal Forearm Arteriovenous Fistula



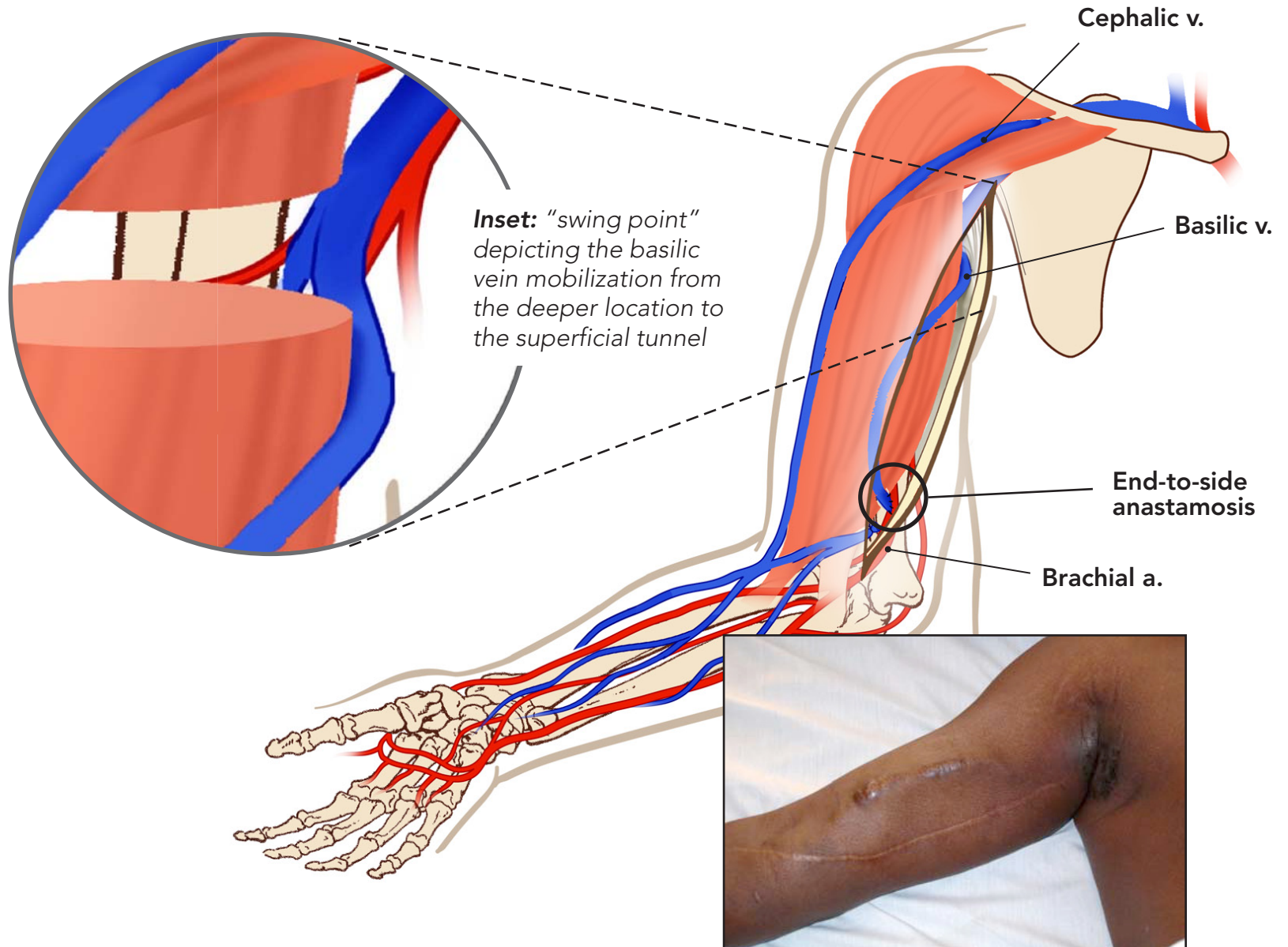
Anastomosis between proximal radial artery and median antecubital vein



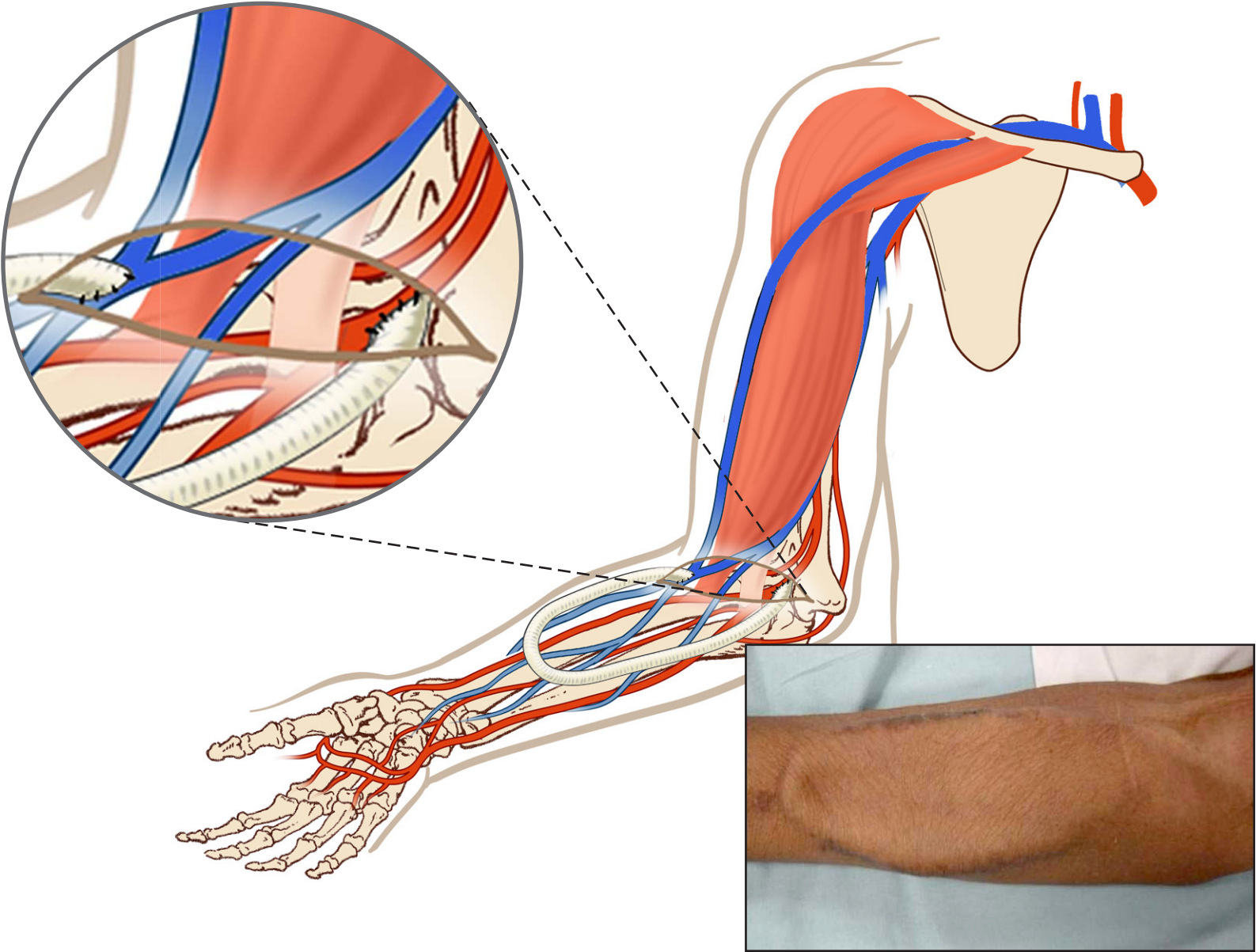
Brachiocephalic Arteriovenous Fistula



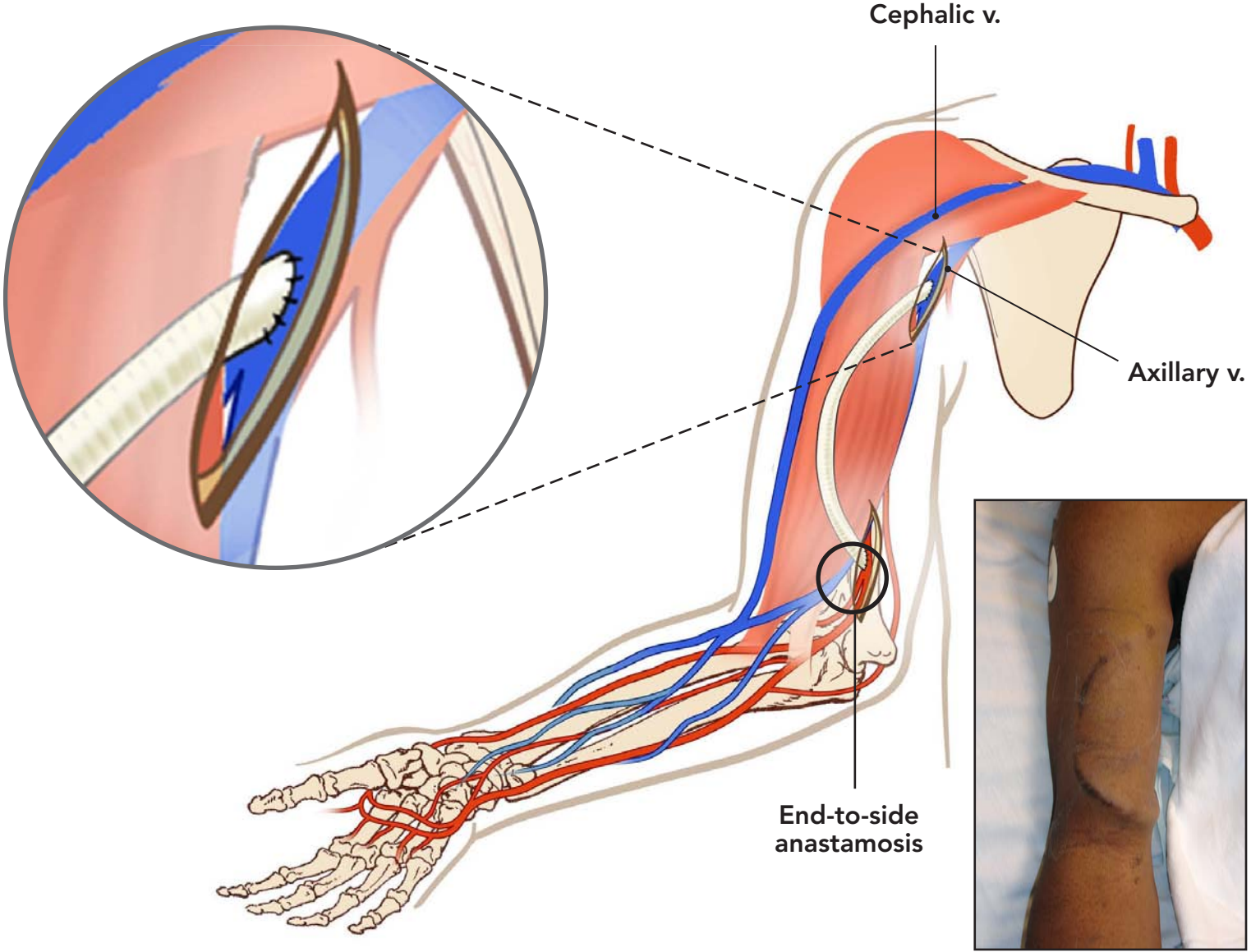
Transposed Basilic Vein Arteriovenous Fistula



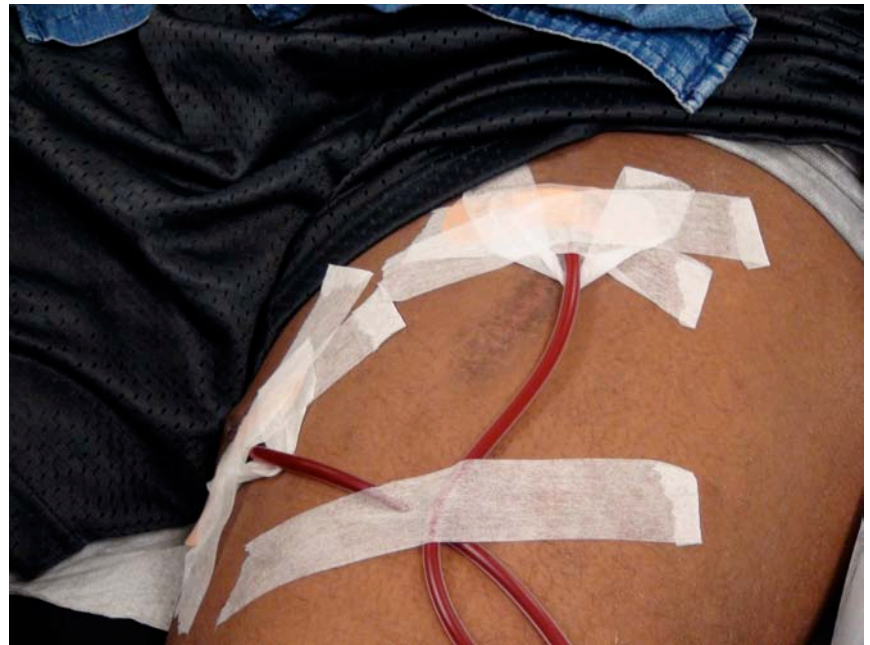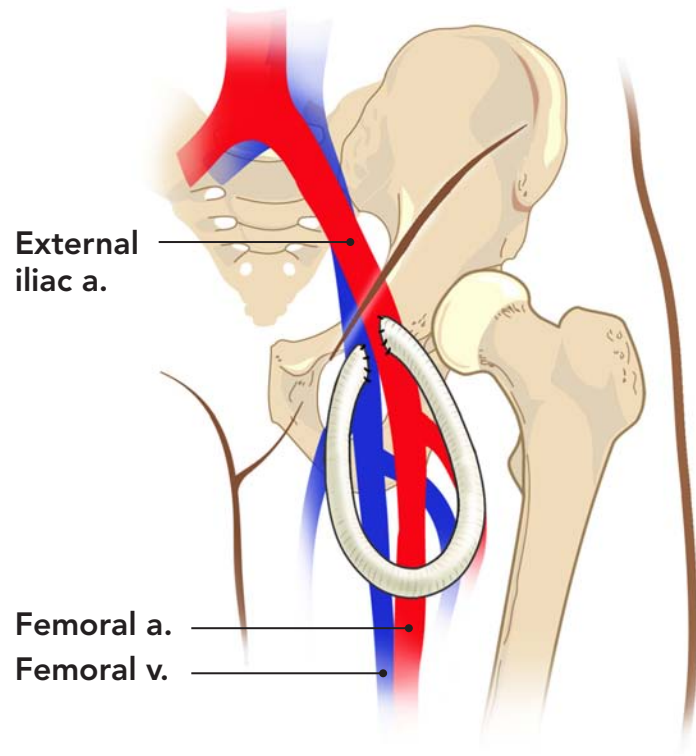
Forearm Loop Arteriovenous Graft



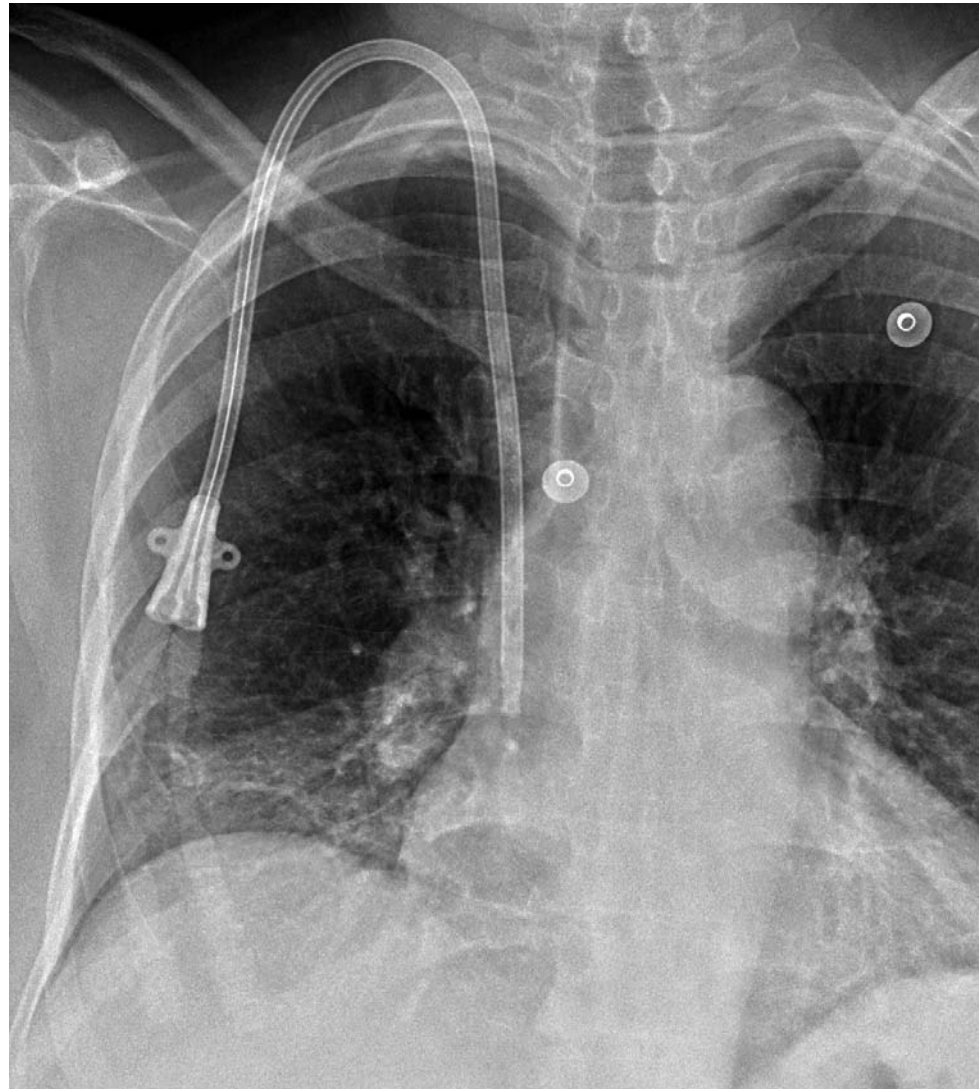
Upper Arm Arteriovenous Graft



Thigh Arteriovenous Graft



The catheter is placed in the right internal jugular vein with a smooth curve in the subcutaneous tunnel. The tip of the catheter is placed in the right atrium to achieve adequate blood flow during hemodialysis.



TUNNELED CATHETERS

Tunneled central vein catheters are often used as temporary accesses for hemodialysis. Tunneled catheters can be placed at several sites. The preferred site is the right internal jugular vein.

Other sites often used are the left internal jugular vein and femoral vein. Subclavian vein is accessed only if the possibility of placing an ipsilateral permanent arteriovenous access in the upper extremity is unavailable. The risk of developing central vein stenosis is very high with a subclavian vein catheter.

Rarely, tunneled catheters are placed in the inferior vena cava through a translumbar or transhepatic approach.

Potential complications of a tunneled catheter are:

- Malfunction due to mechanical causes like
 - Poor placement technique
 - Retraction with or without exposure of the cuff
 - Cracked hub or broken clamps
 - Thrombosis/Fibrin sheath formation
- Infection
 - Exit site
 - Tunnel infection
- Central vein stenosis

Early recognition of these complications is important to prevent:

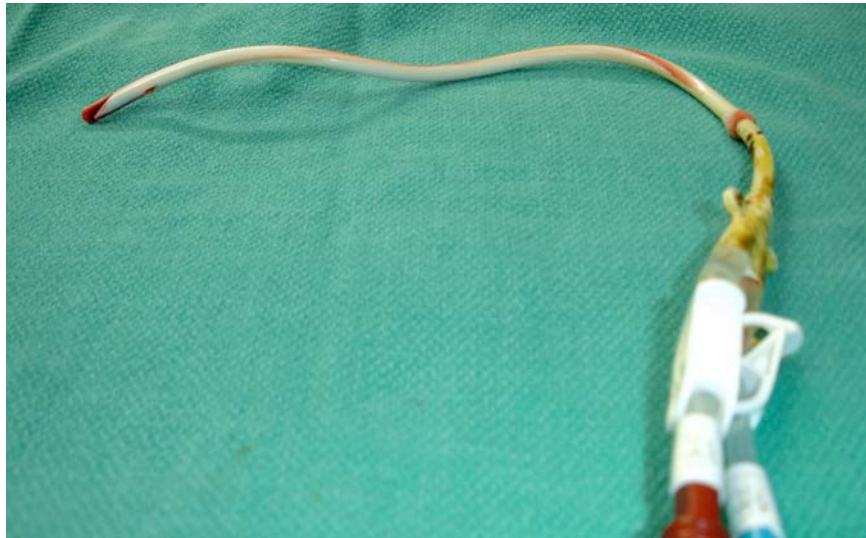
- Loss of the vascular site if the catheter falls out
- Inadequate dialysis clearance
- Bacteremia- and sepsis-related morbidity and mortality

The photographs in this chapter provide adequate tools to enable dialysis access physicians and staff to recognize and identify common problems associated with tunneled catheters.

Left-sided Catheter

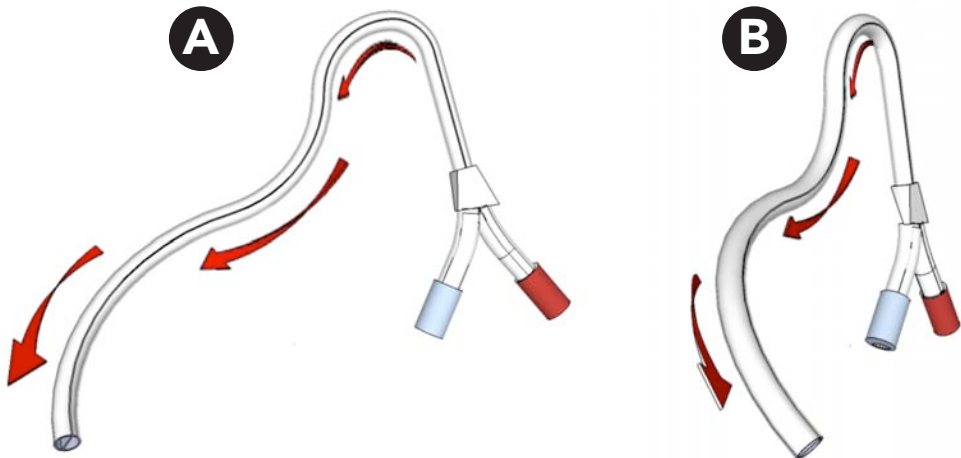
Actual left internal jugular vein tunneled catheter removed from a patient showing multiple angulations along its course.

The complex anatomical pathway traversed by left internal jugular vein catheters may be responsible for higher incidence of catheter malfunction and thrombosis.



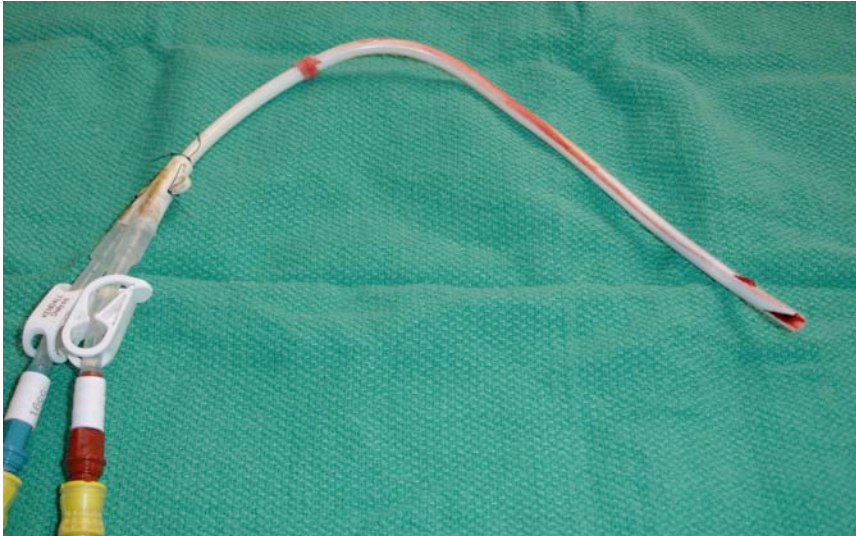
A: Schematic representation of the angulations caused by the left internal jugular vein, left brachiocephalic vein and superior vena cava.

B: Schematic representation of the additional angulation, as the catheter traverses the mediastinum and is not visualized on frontal projection radiograph.



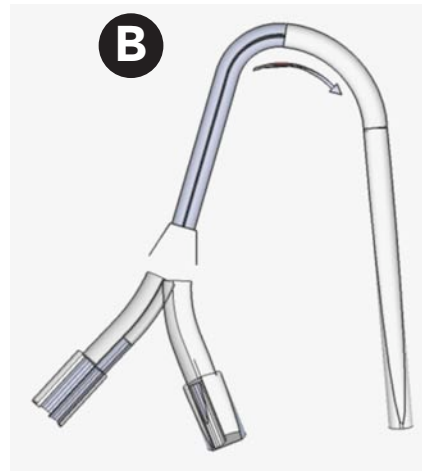
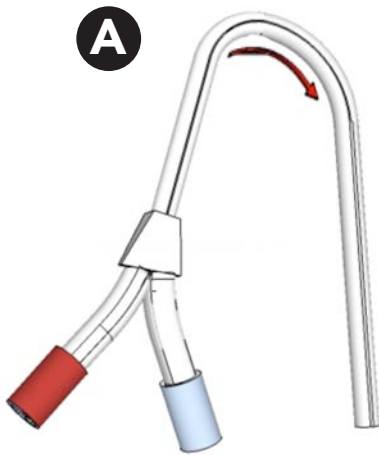
Computer generated figures designed by Vipul Vachharajani

Right-sided Catheter



Actual right internal jugular vein tunneled catheter removed from a patient showing a single smooth curve.

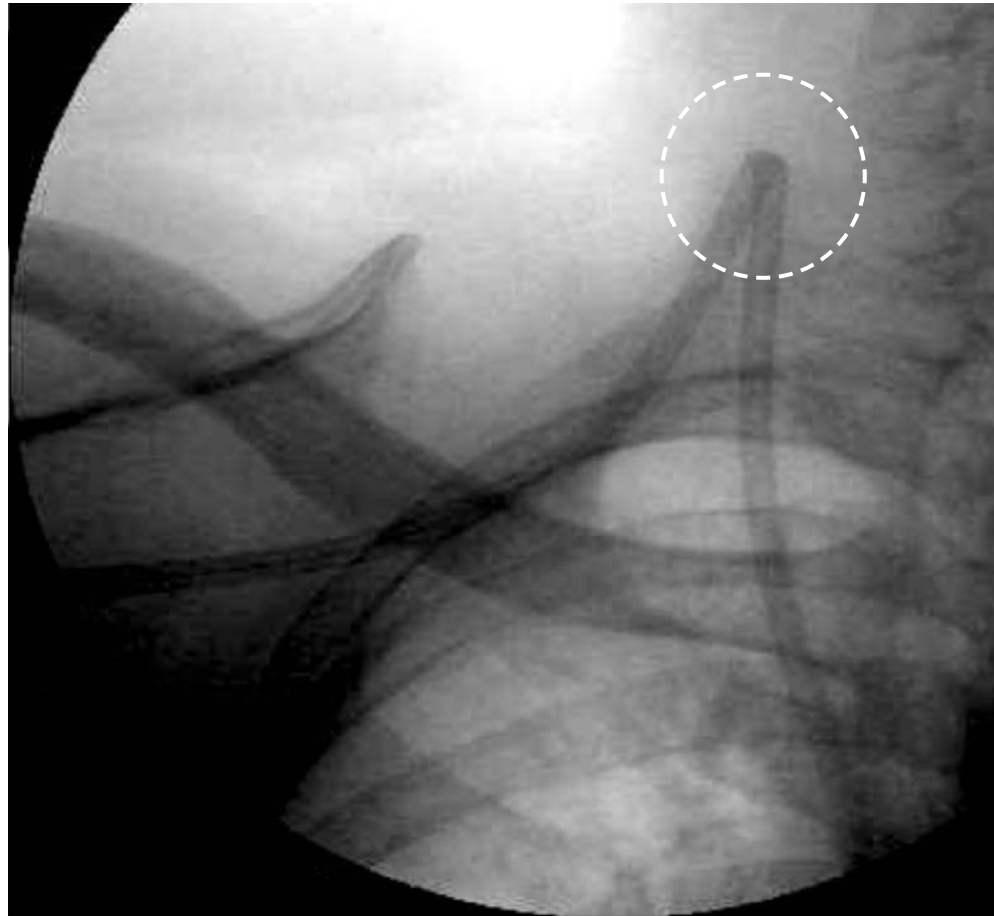
- A:** Schematic representation of the smooth curve
- B:** Cross-sectional schematic representation of the smooth curve



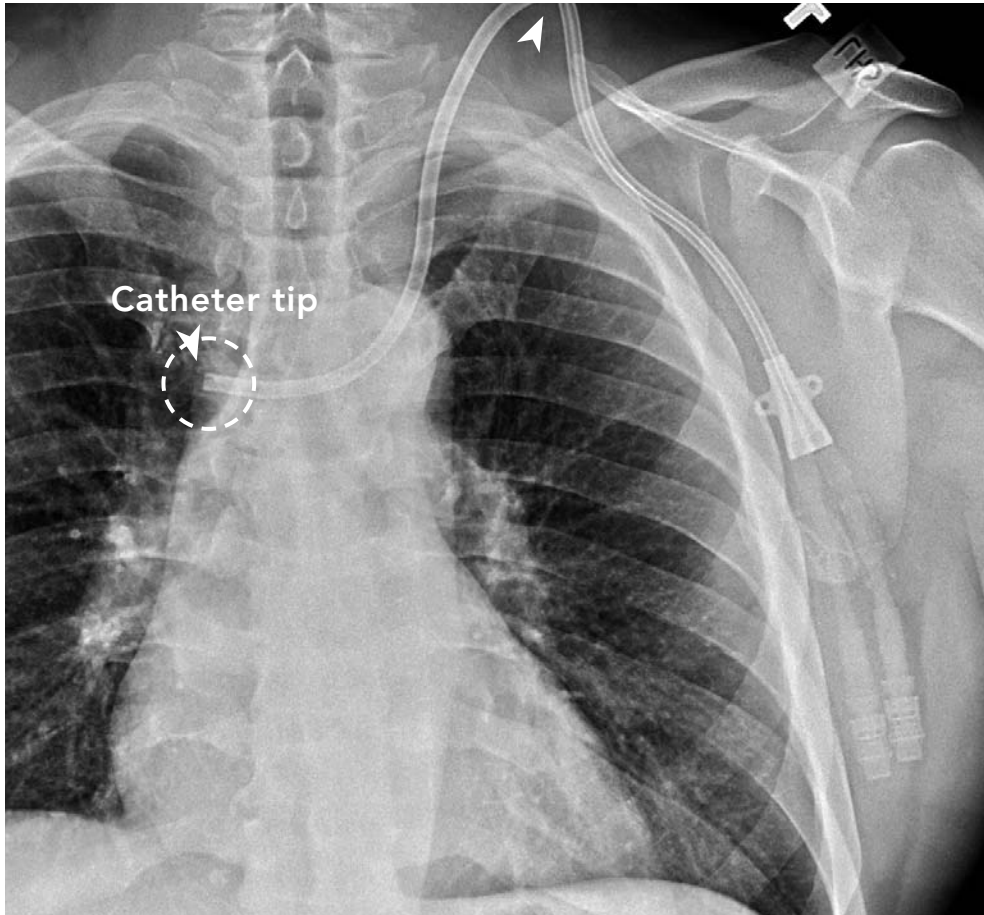
Computer generated figures designed by Vipul Vachharajani

Kinked Catheter

The catheter in the subcutaneous tunnel is acutely kinked causing mechanical obstruction to the blood flow.



Malpositioned Tip of Catheter

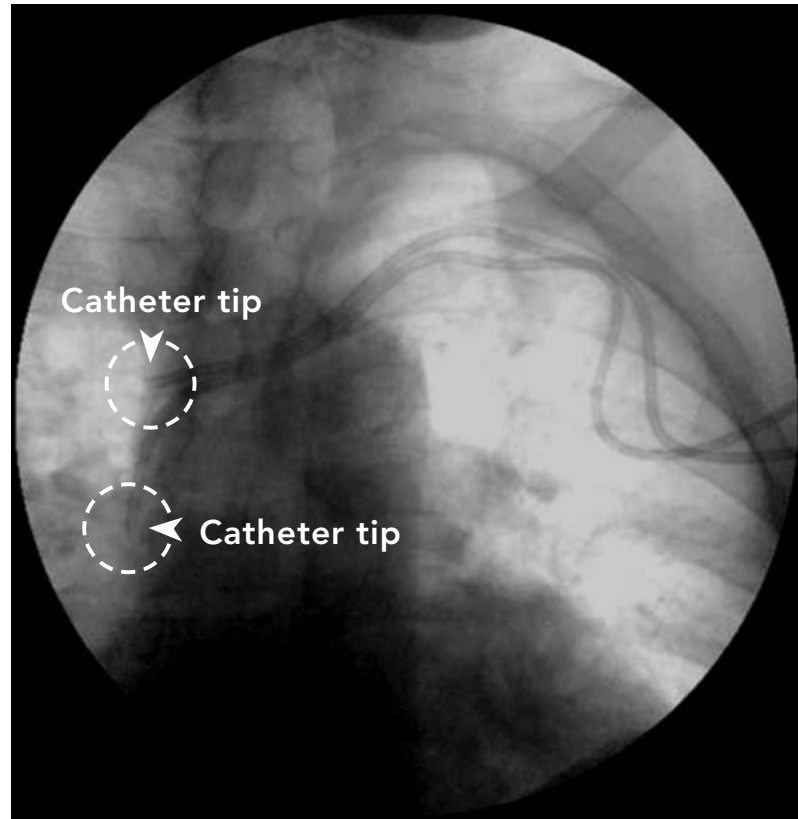


Left internal jugular catheter with kink in the subcutaneous tunnel (arrow). The tip is placed in the left innominate (brachiocephalic) vein.

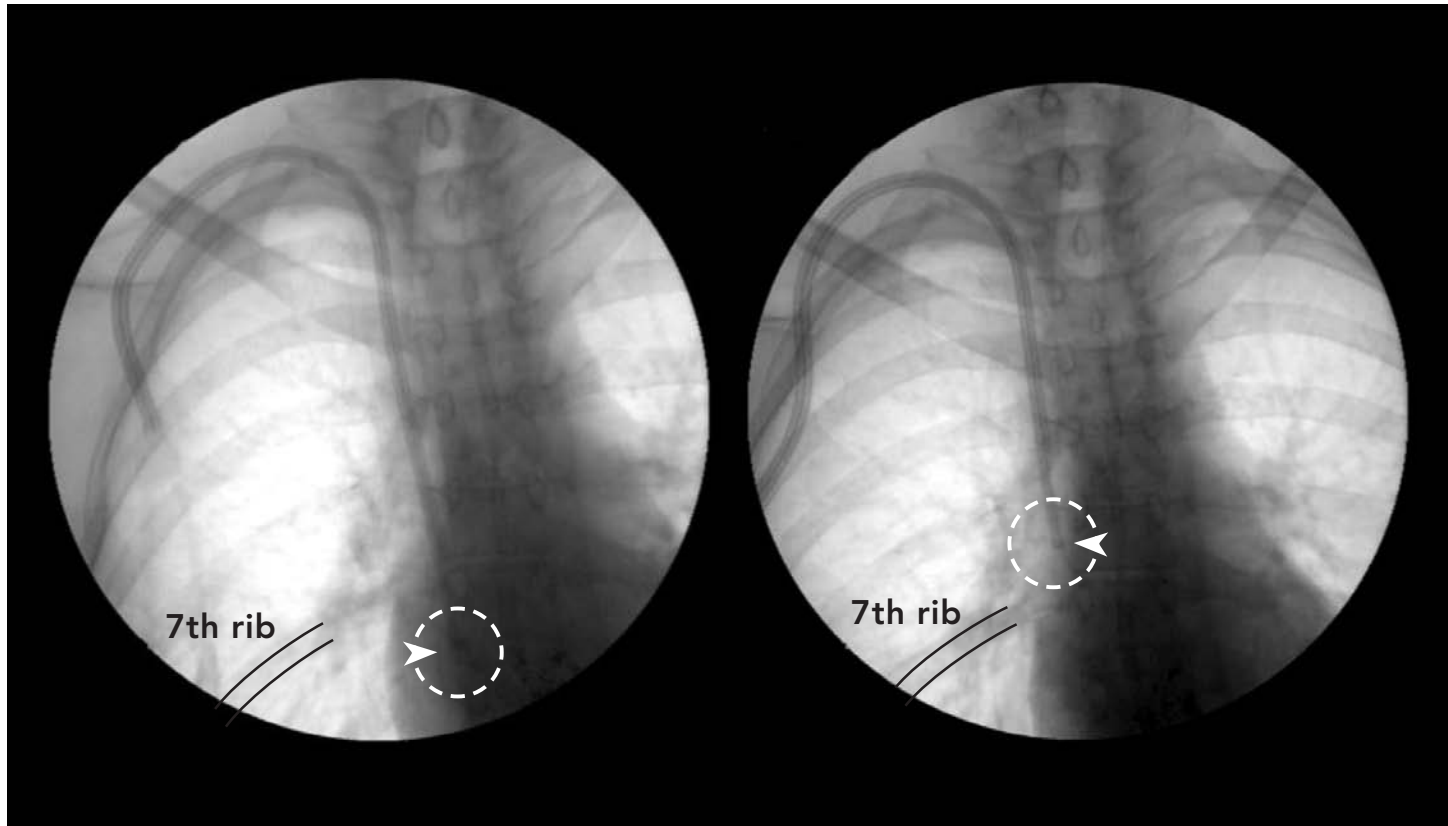
The catheter is unlikely to provide adequate blood flows for dialysis.

Malpositioned Tip of Catheter

Tesio catheter with malpositioned tips. Catheter tips are in the proximal superior vena cava.

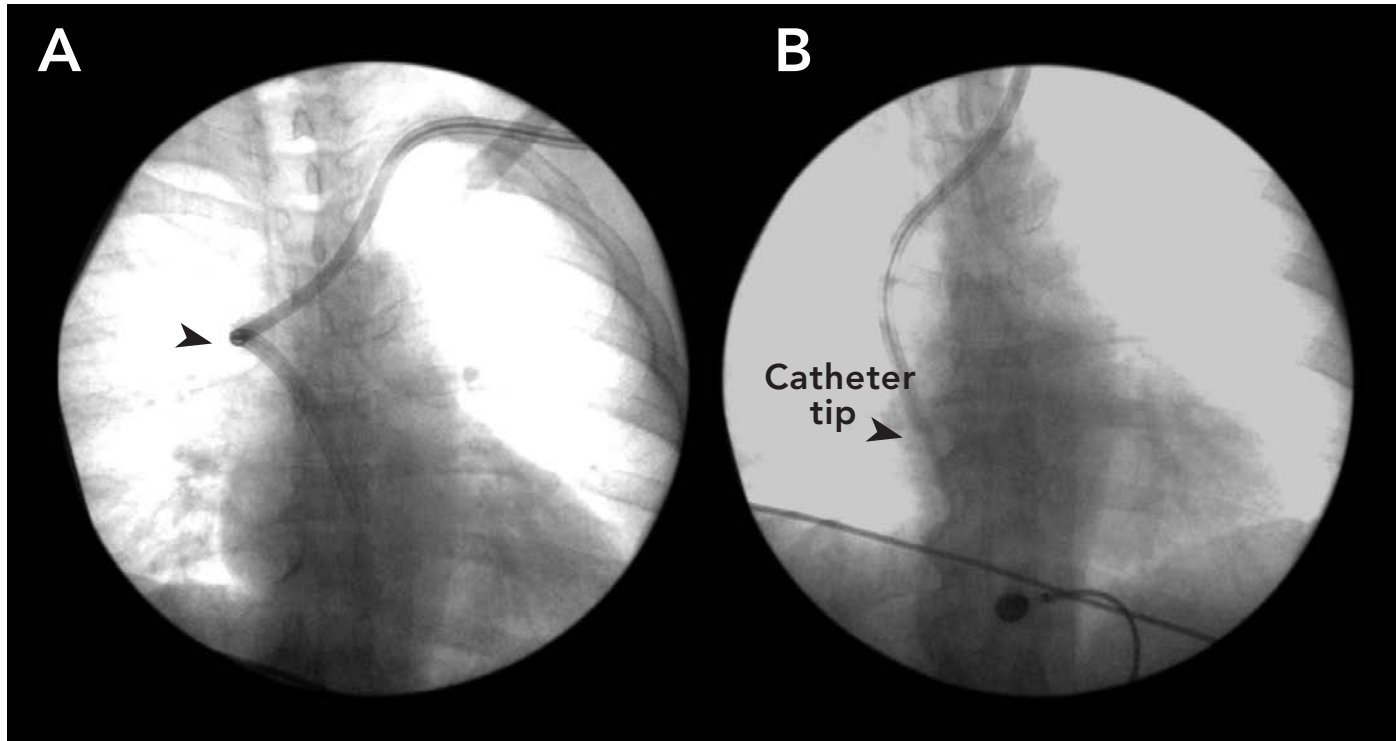


Catheter Tip Retraction



The catheter tip often retracts from a supine to an erect position, especially if it is anchored on breast or pectoral fat. Thus, the tip of the catheter should be placed in the right atrium.

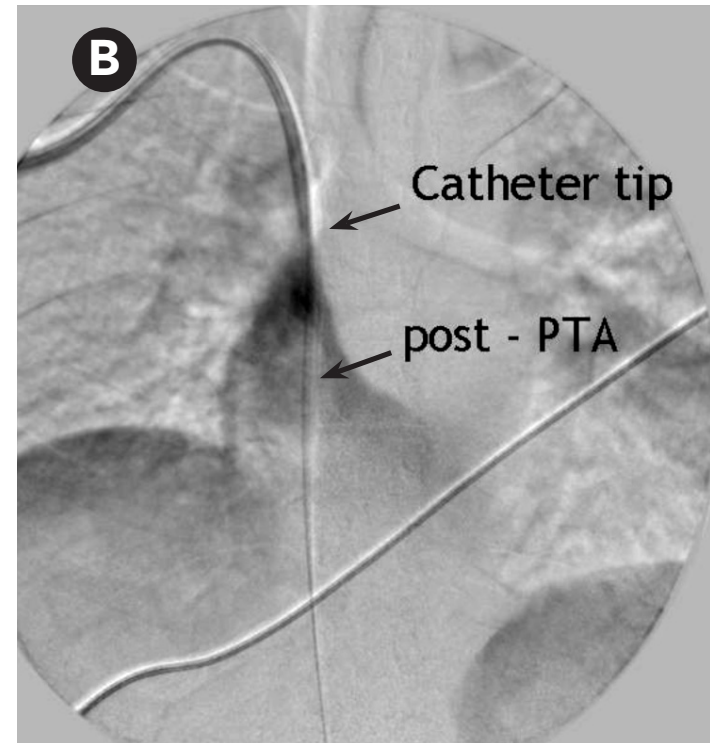
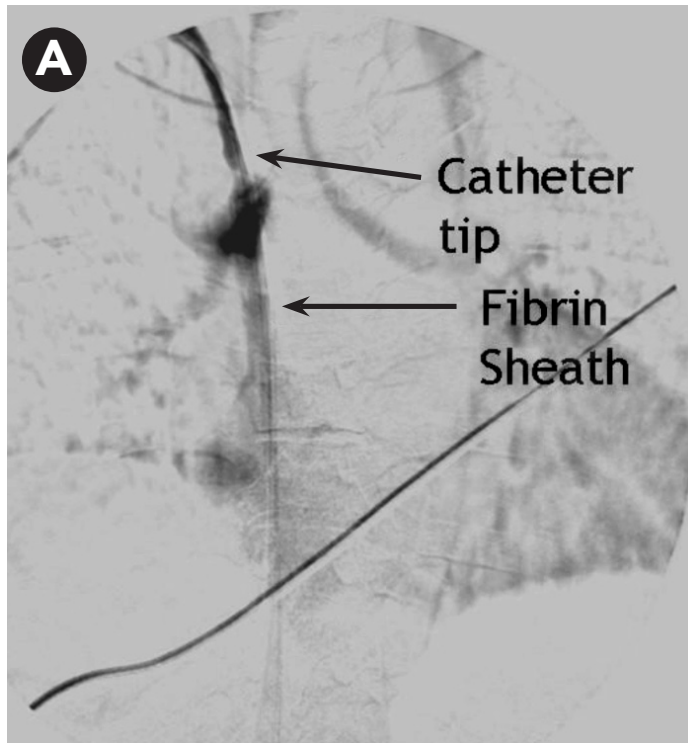
Catheter Tip in Azygos Vein



A: The tip of the left internal jugular catheter is placed in the azygos vein. An acute angle curve is noted with twisting of the catheter at the junction of the superior vena cava and azygos vein.

B: The catheter tip has been repositioned in the right atrium.

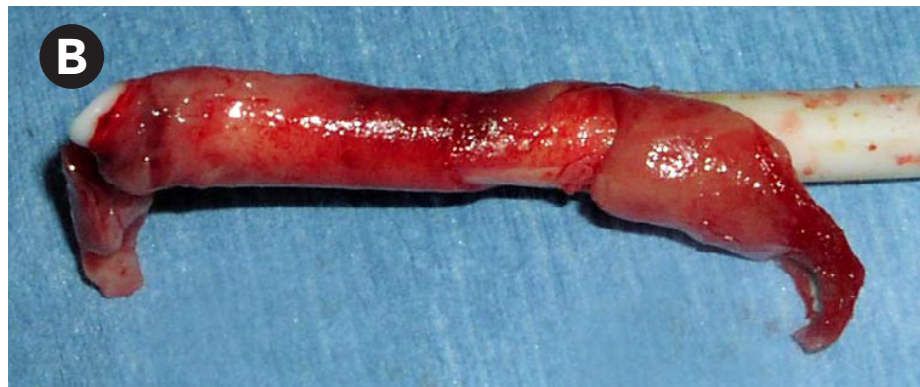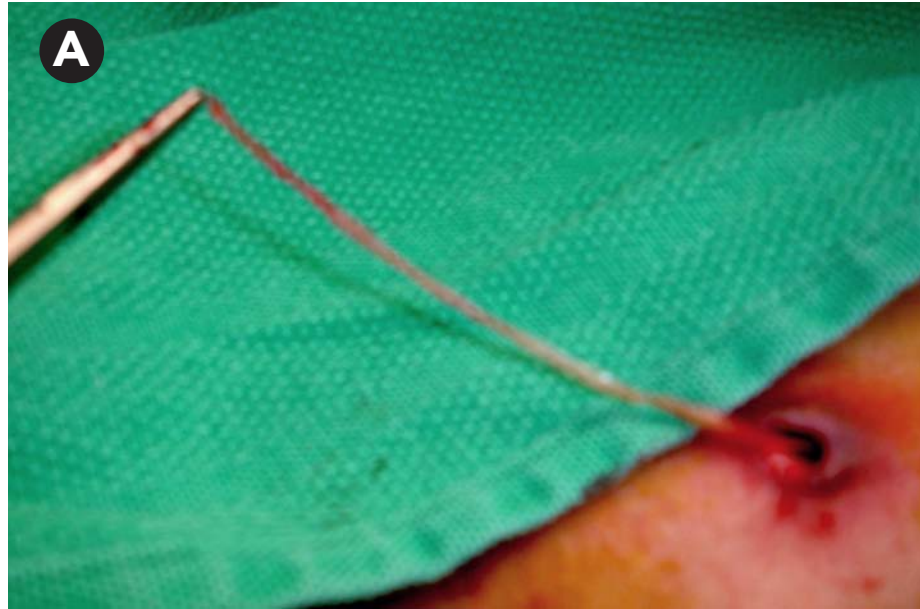
Fibrin Sheath Formation



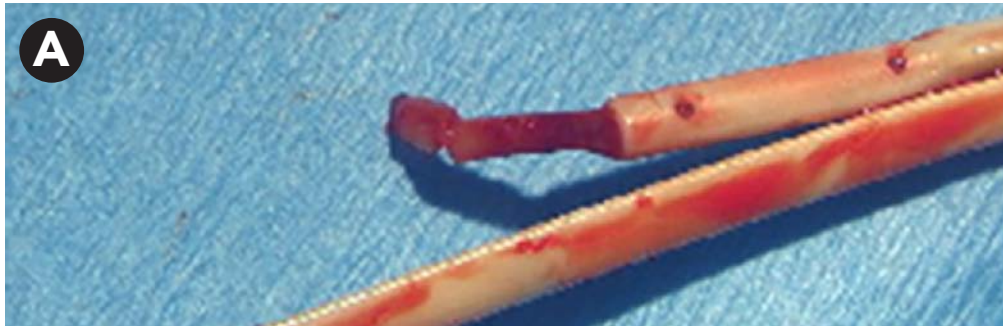
Fibrin sheath develops around the catheter. The sheath acts like a one-way valve and prevents adequate and free pulling of blood through the catheter. The fibrin sheath can be disrupted either with an angioplasty or can be stripped using a snare device. The pre-angioplasty image above **(A)** shows poor filling of the right atrium and the contour of the catheter is maintained beyond the catheter tip. Post-angioplasty image above **(B)** shows the contrast flowing freely in to right atrium. The fibrin sheath can extend from the cuff to beyond the catheter tip.

Fibrin sheath

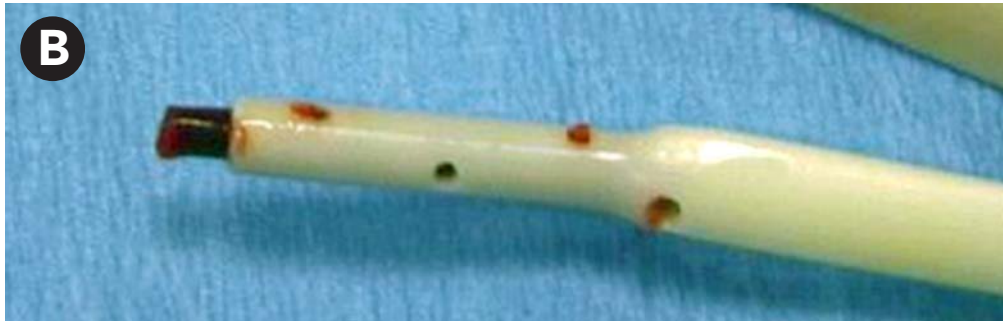An intact fibrin sheath pulled out along with the catheter. A fibrin sheath is a flimsy fibroepithelial tissue that extends from the cuff (A) to the tip of the catheter (B).



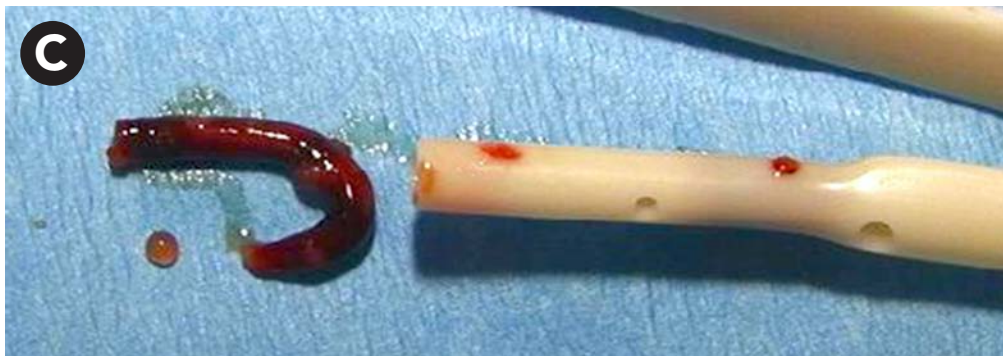
Intraluminal Thrombus



Fibrin sheath extending beyond the tip of the catheter and occluding it completely.



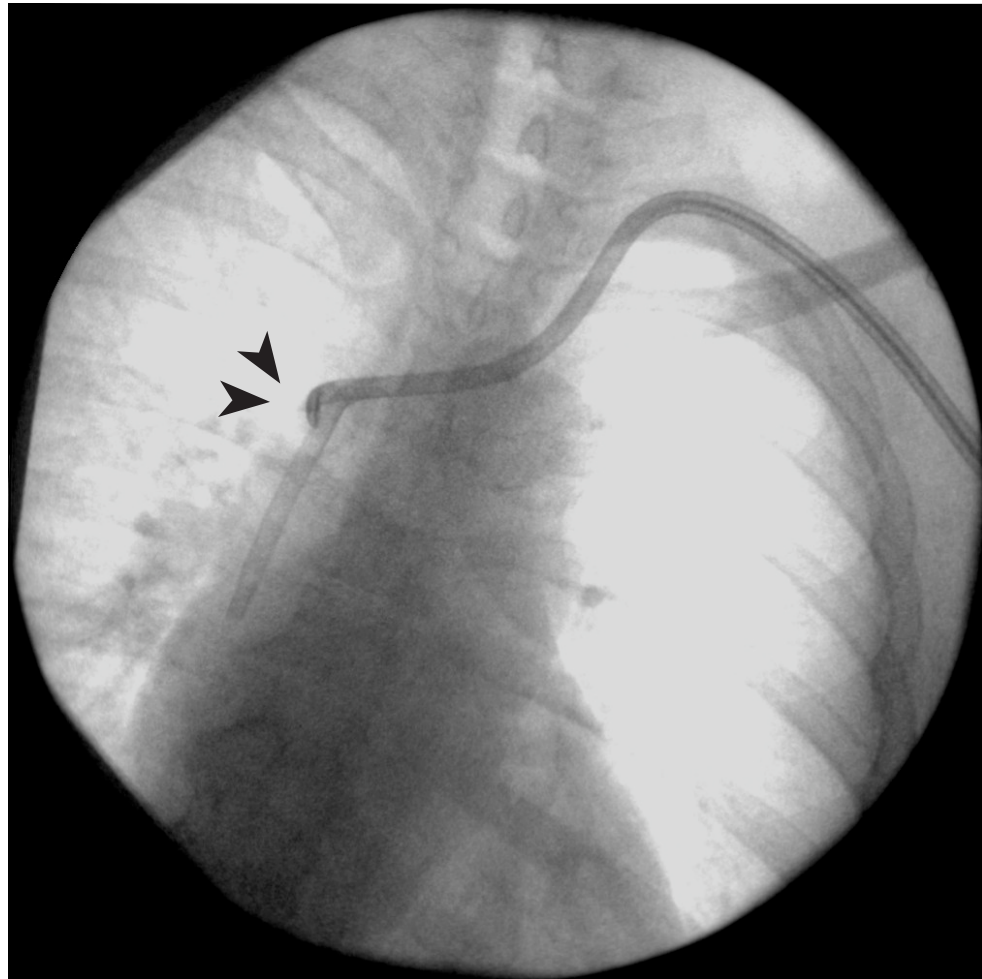
An organized thrombus occluding the tip of the catheter.



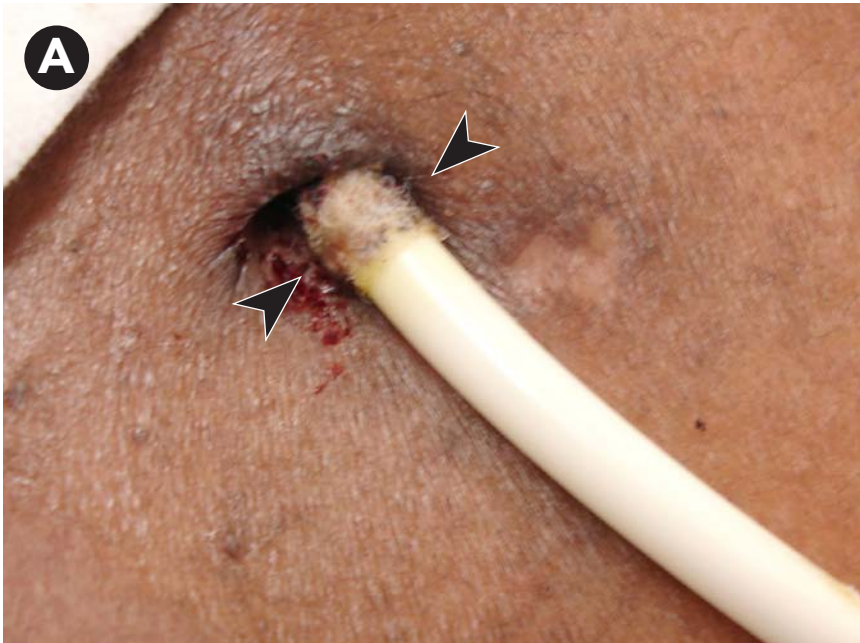The organized clot has been extruded from the catheter.

Split Tip catheter

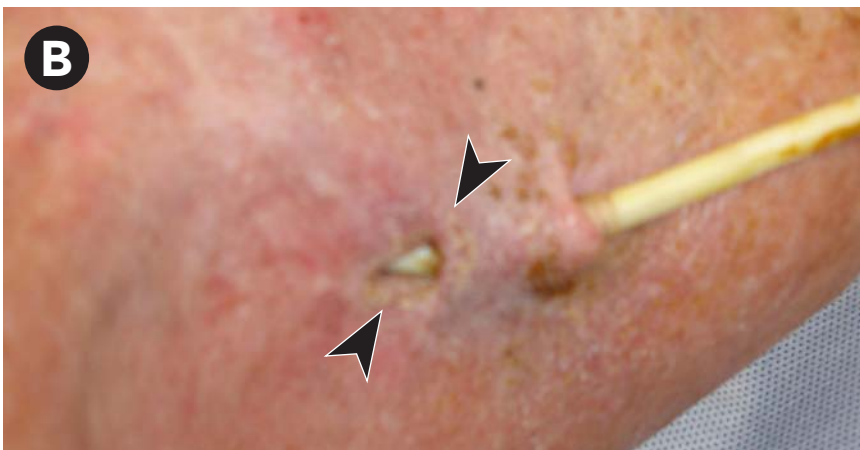A split tip tunneled catheter placed in the left internal jugular vein. The arterial tip is curled up (arrowheads) and kinked leading to high dialysis arterial pressures and poor delivery of blood flow during dialysis.



Exposed Cuff



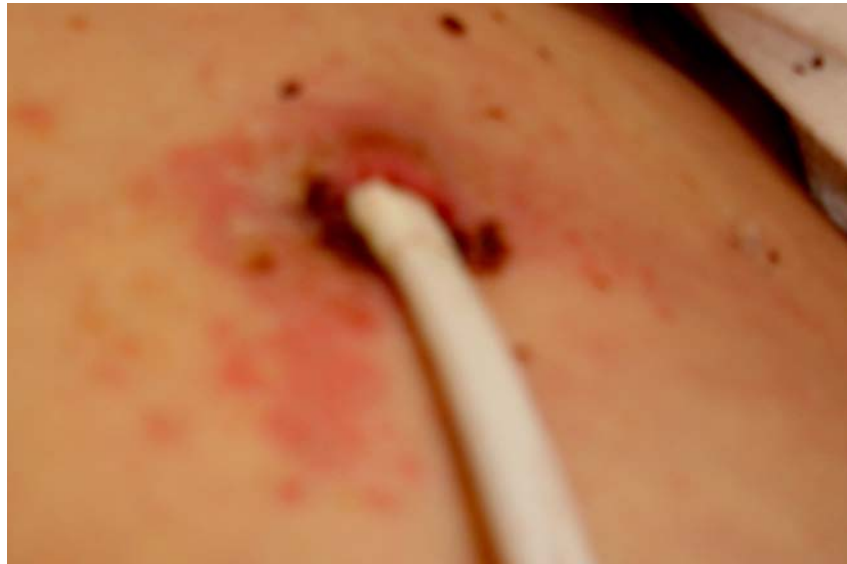A: The cuff of the catheter is exposed at the exit site. The exit site should be evaluated prior to each dialysis session. A catheter with an exposed cuff can be easily pulled out and can lead to loss of a vital vascular access site. The exposed catheter cuff would also suggest that the tip is no longer at the proper location and delivery of blood through this catheter may not be adequate. The replacement of the catheter over a guide wire can be easily performed with proper anchoring and the patient can return for dialysis therapy on the same day.



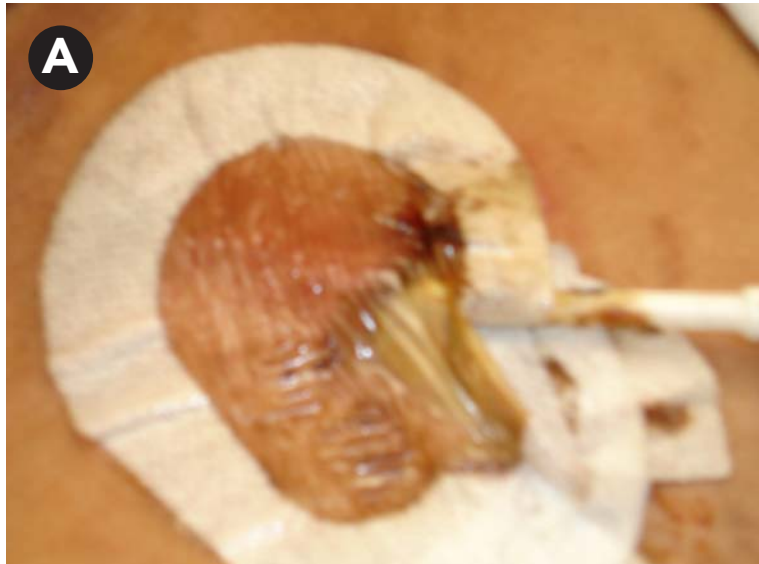B: Disrupted subcutaneous tunnel (arrowheads) with exposed catheter cuff at the exit site.

Exit Site Infection

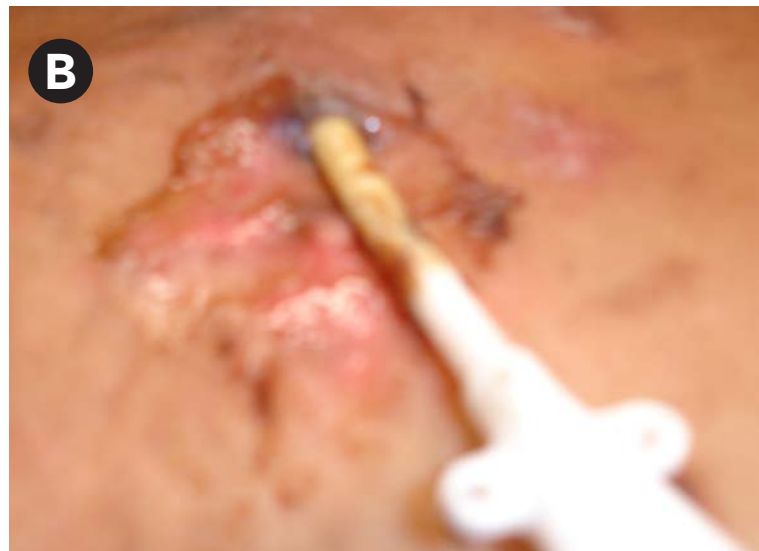Exit site erythema with crusting suggestive of infection or allergic reaction to topical ointment or tape. The exit site should be evaluated prior to every dialysis therapy for early signs of infection. The exit site infection can spread through the subcutaneous tunnel causing bacteremia, sepsis and worsening morbidity and mortality.



Tunnel Infection



A: Purulent fluid collection under the dressing suggestive of infection.



B: Purulent secretion, erythema over the tunnel and skin changes secondary to infection in the subcutaneous tunnel.

The catheter must be removed promptly for effective antibiotic therapy and morbidity reduction.

ARTERIOVENOUS FISTULA

Arteriovenous fistula (AVF) is the preferred dialysis access because of a lower incidence of associated morbidity and mortality. An AVF is surgically created by connecting the artery and vein. Approximately 8-12 weeks are required for an AVF to mature completely. The sites available for creating an AVF are limited, requiring proper handling and care during hemodialysis therapy.

The common problems associated with an AVF are:

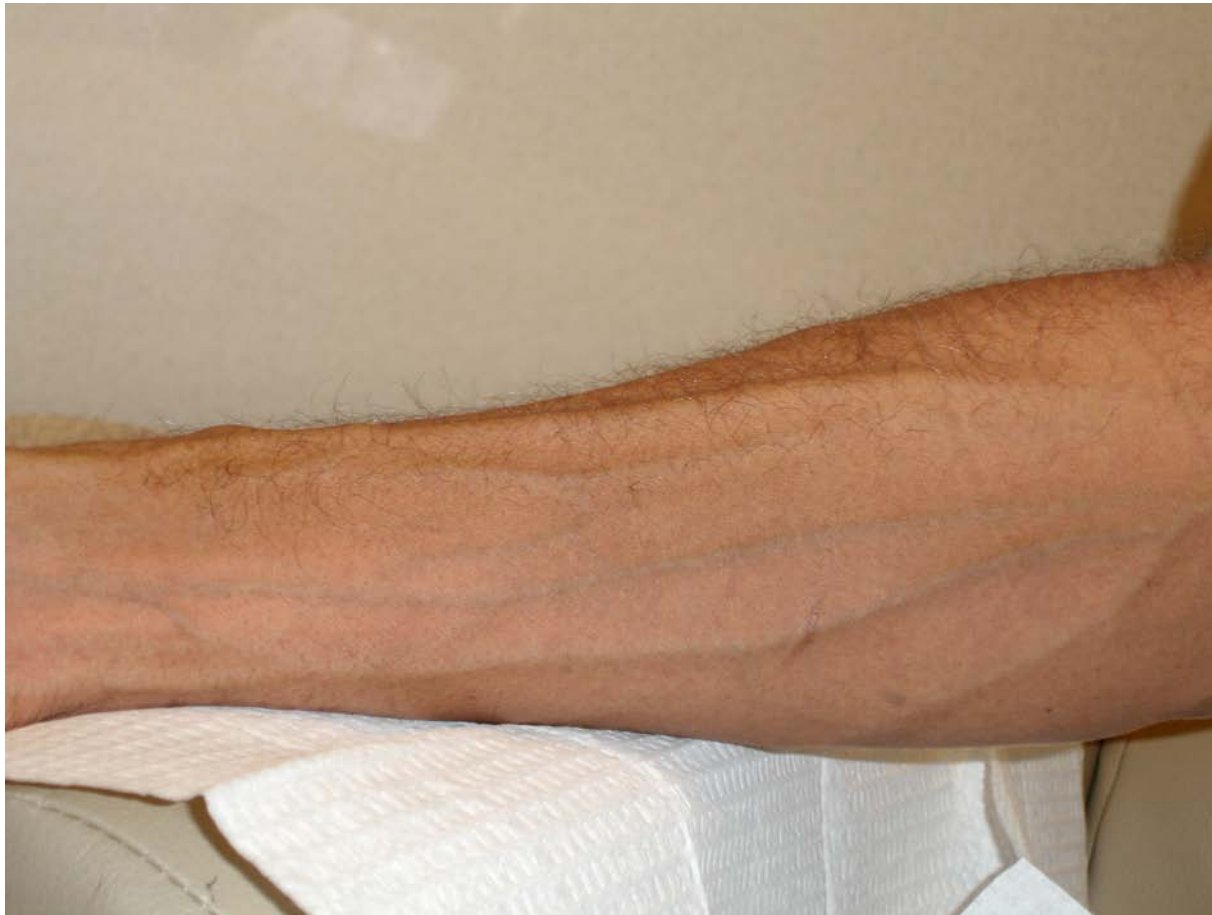- Poor or delayed maturation
- Infiltration and hematoma formation during hemodialysis secondary to improper cannulation technique
- Stenosis at the "swing site," the segment of the vein mobilized for arterial anastomosis in the creation of an arteriovenous fistula
- Stenosis due to neo-intimal hyperplasia, eventually leading to thrombosis
- Aneurysmal dilatation either due to vessel trauma from frequent needle punctures and/or a proximal stenosis
- Infection
- Steal syndrome due to ischemia of the distal extremity
- High output congestive heart failure from large arteriovenous fistula
- Central vein stenosis

Many of these problems can be prevented with proper cannulation techniques and regular monitoring and surveillance during hemodialysis therapy. Early diagnosis and timely referral requires understanding and recognizing the pathology.

The current chapter provides visual aids to commonly seen pathology related to arteriovenous fistulas and some of the endovascular interventions that can help maintain their patency. The chapter opens with photographs showing normal vasculature suitable for creating an AVF. Ideally, an AVF should be created early enough to allow the AVF to mature and avoid the need to place a central venous catheter for dialysis therapy. The preservation of vessels in chronic kidney disease patients is the key to creating a functional AVF.

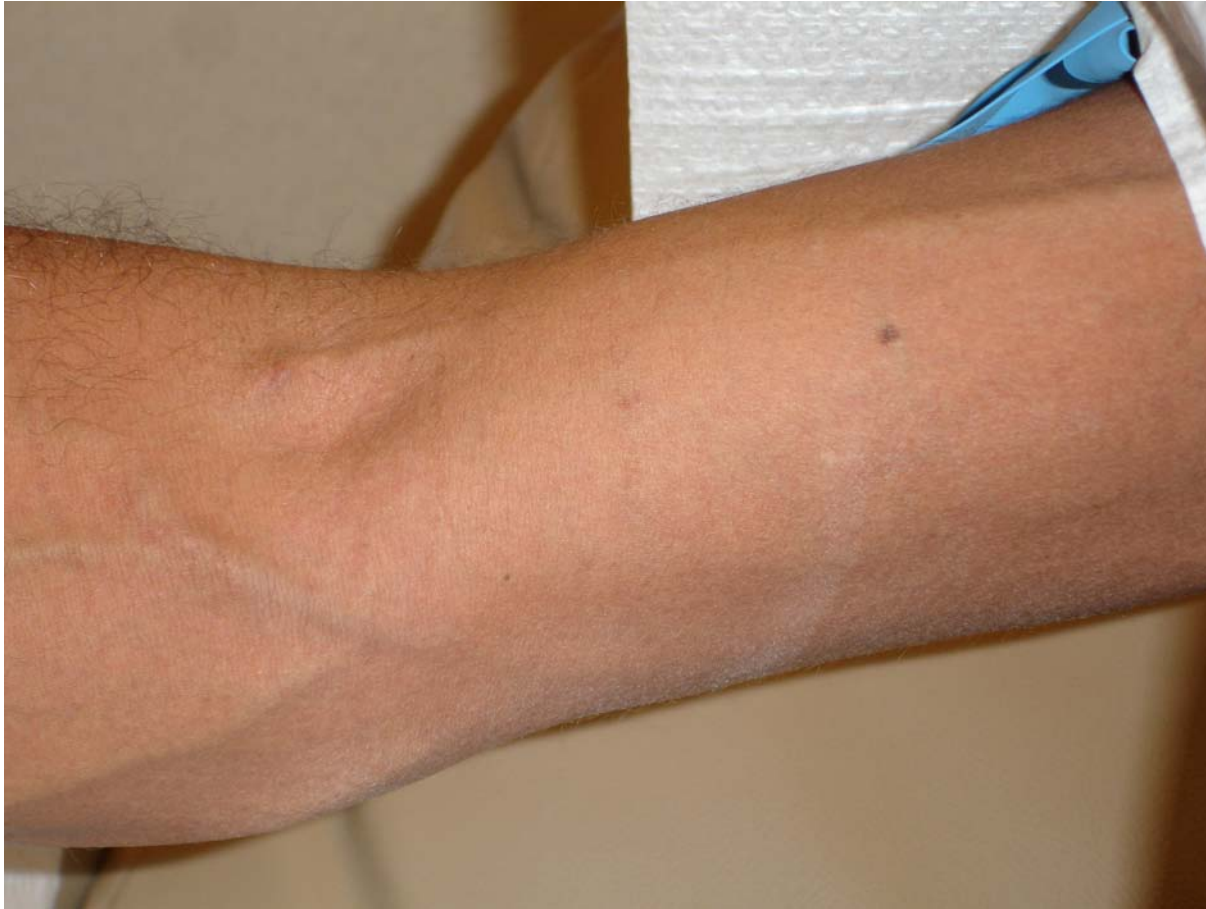The remaining images highlight some of the common problems encountered in a busy hemodialysis clinic.

Well-preserved Forearm Veins



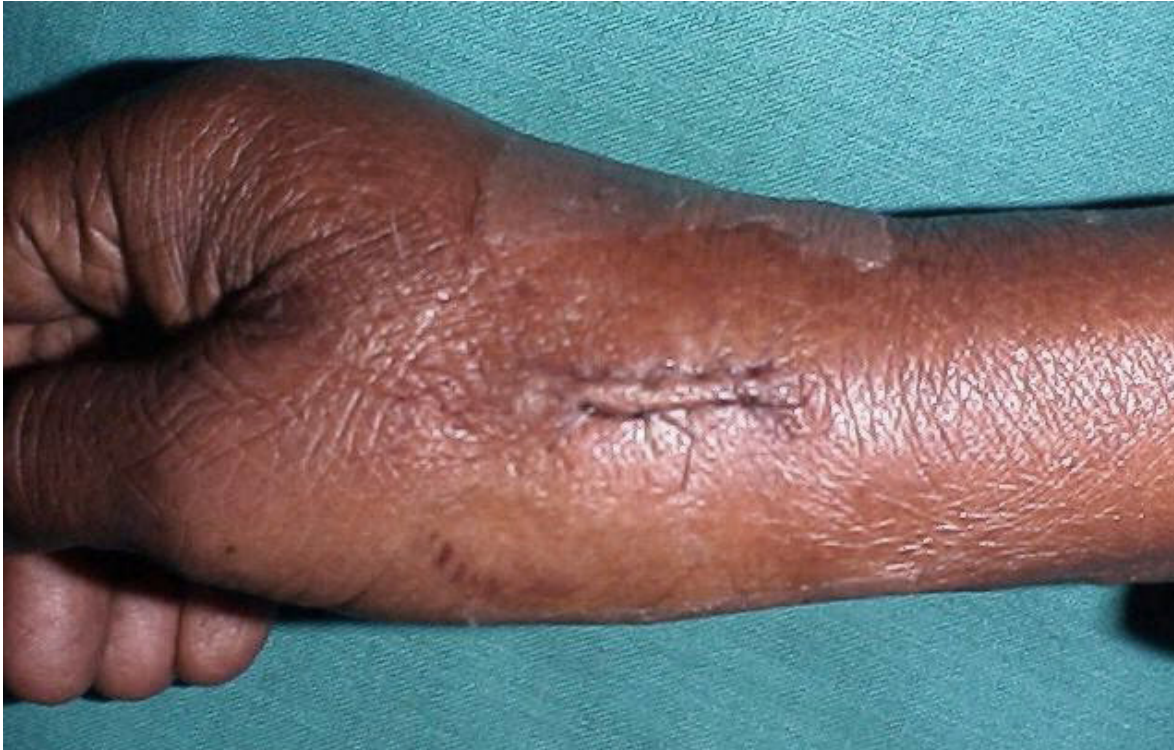Well-preserved veins in the forearm and upper arm for creating a functional arteriovenous fistula. Vessel preservation is essential in chronic kidney disease patients.

Well-preserved Upper Arm Cephalic Vein



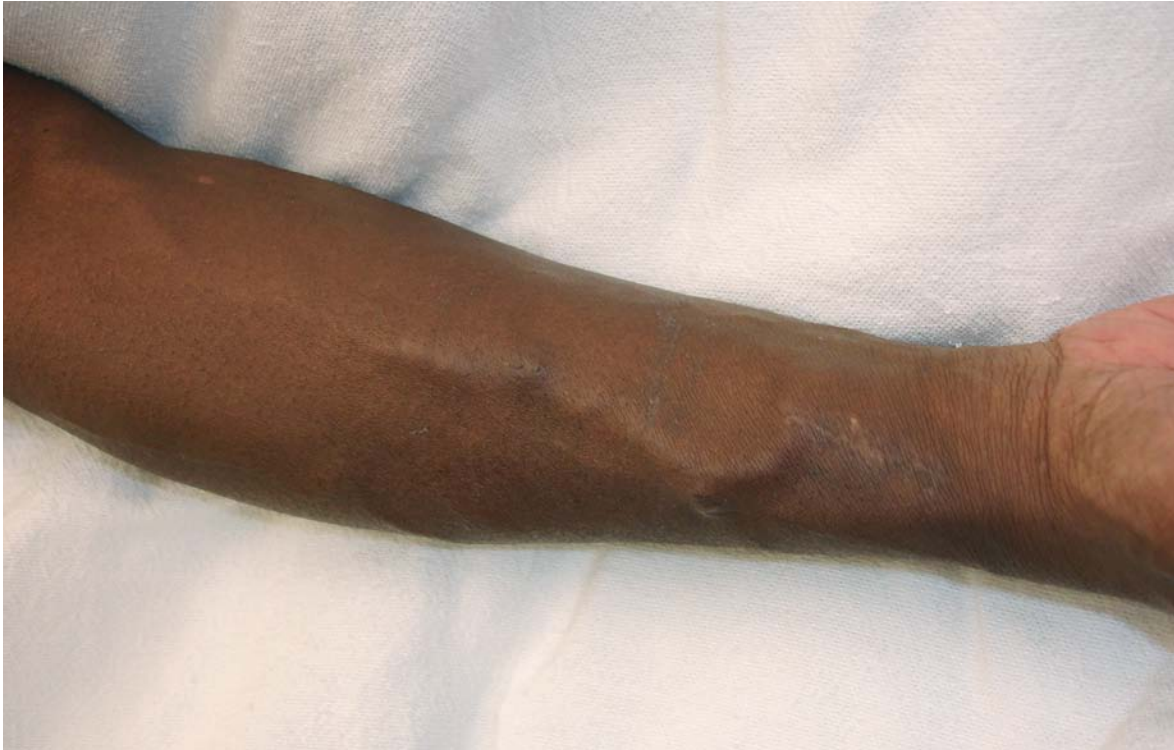Avoiding venipuncture in the forearm and elbow and refraining from placing peripherally introduced central catheters (PICC) are two methods to preserve veins.

Snuff-box AVF



The anastomosis is generally distal to the wrist joint in the snuff-box.

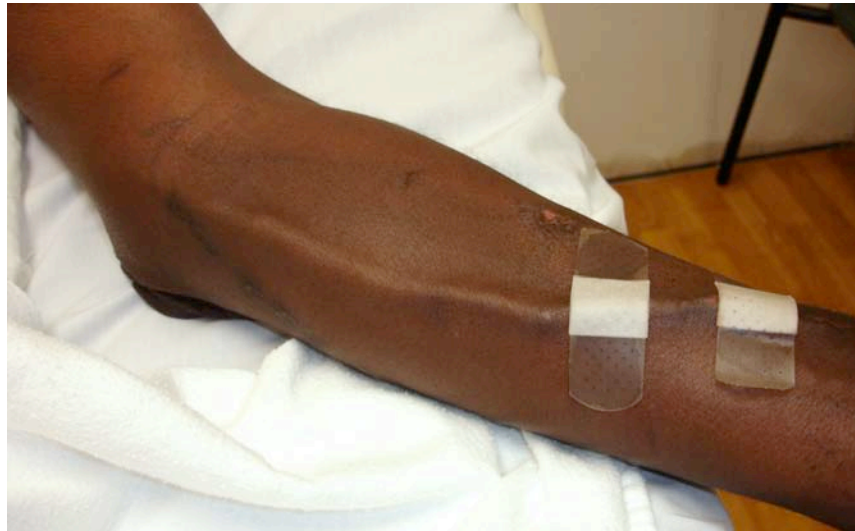
Radiocephalic AVF



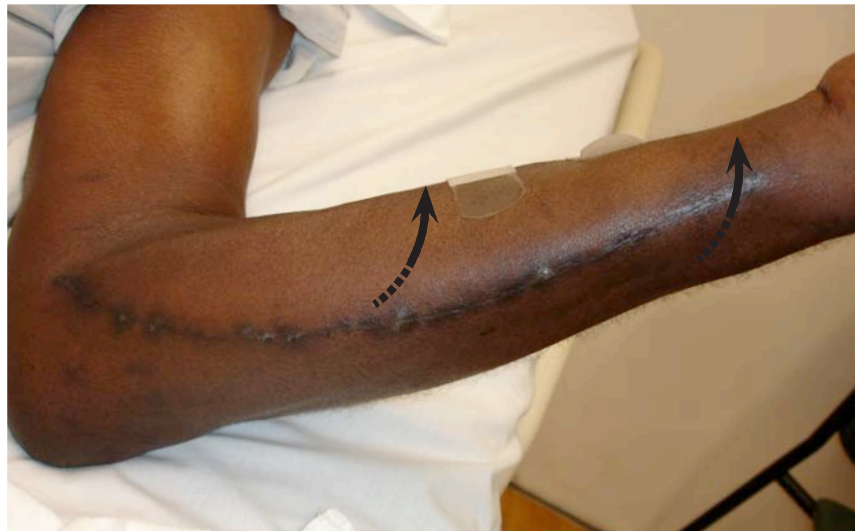A normal radiocephalic fistula with the anastomosis proximal to the wrist joint.

Transposed Forearm Basilic Vein AVF

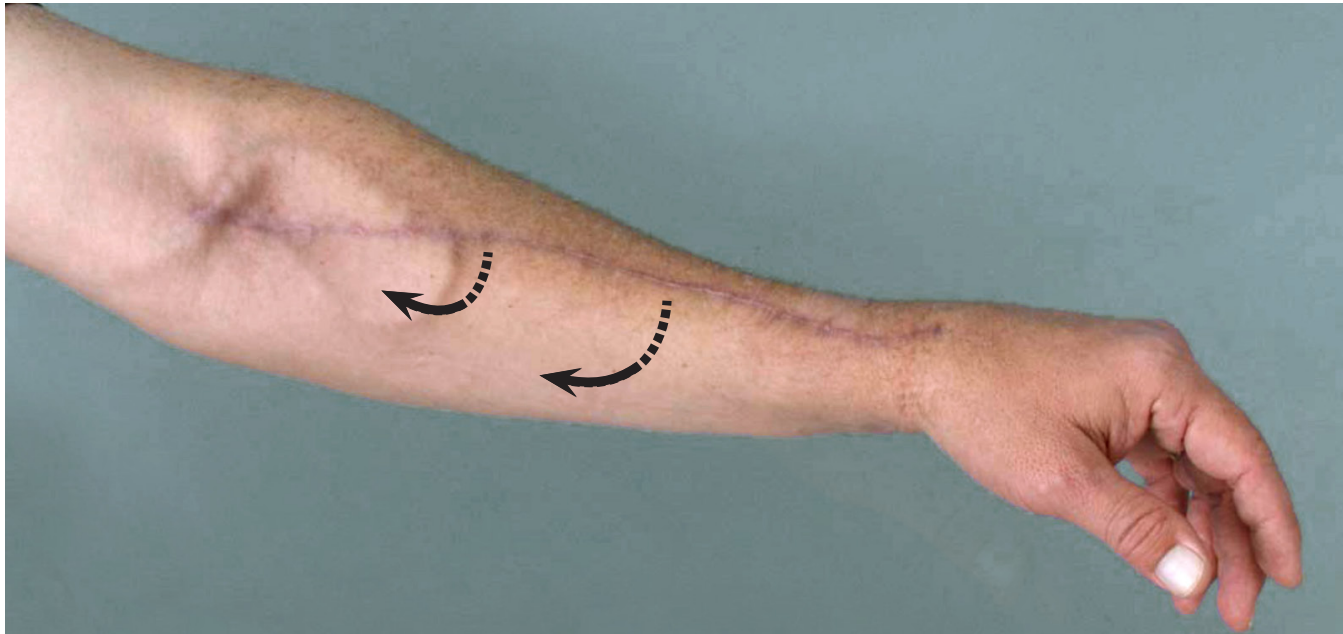
The forearm basilic vein is transposed to create a radio-basilic vein AVF.



The forearm basilic vein (marked by arrows) is transposed to the volar surface of the forearm and anastomosed to the radial artery at the wrist.



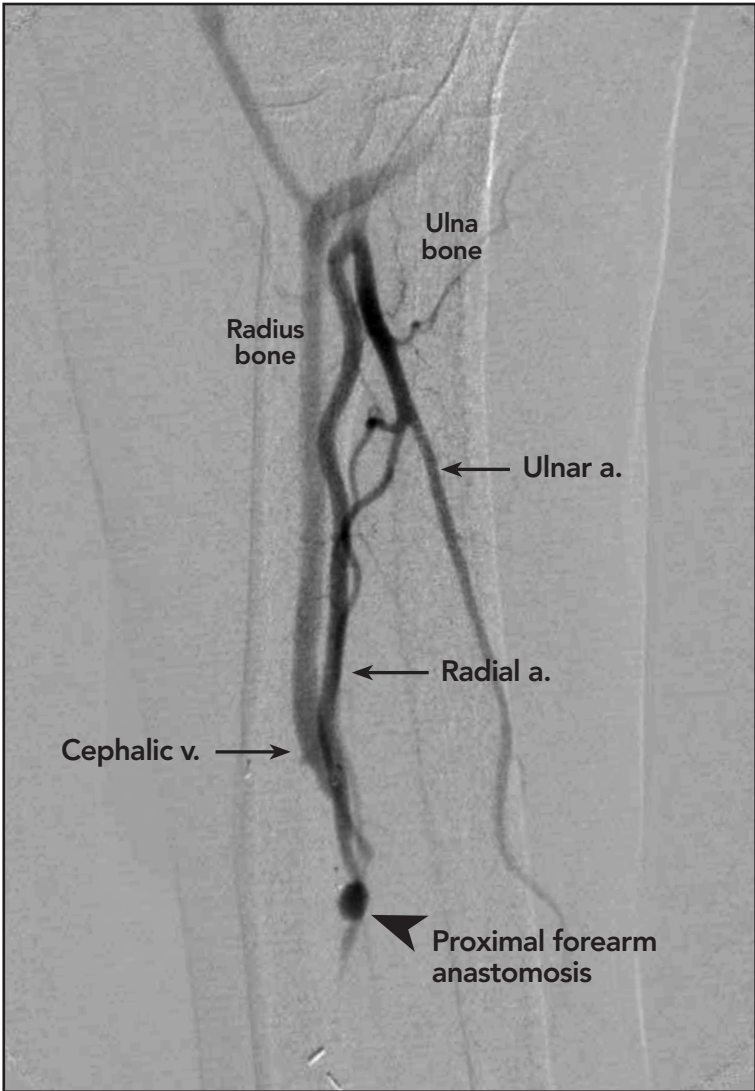
Transposed Forearm Cephalic Vein AVF

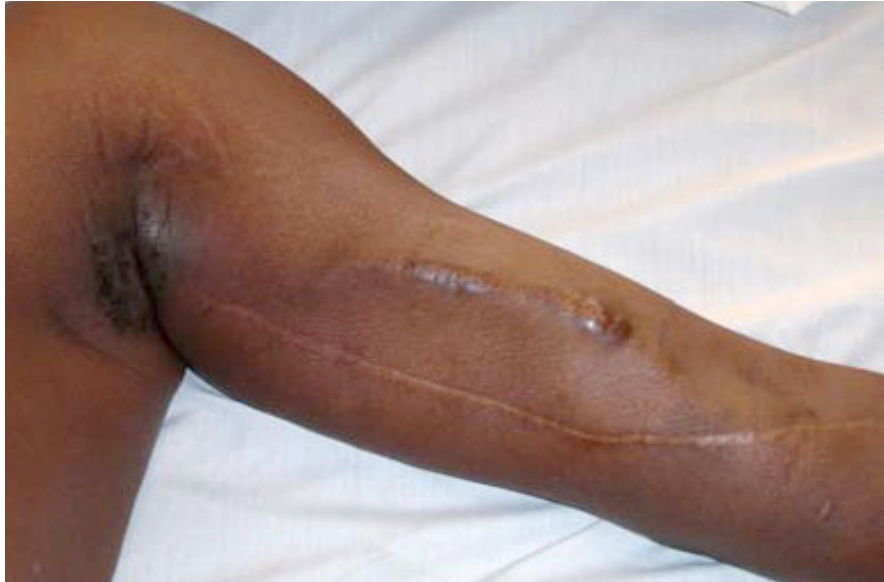

The forearm cephalic vein (marked by arrows) is transposed to create a loop configuration and anastomosed to the brachial artery at the elbow.

Proximal Forearm AVF

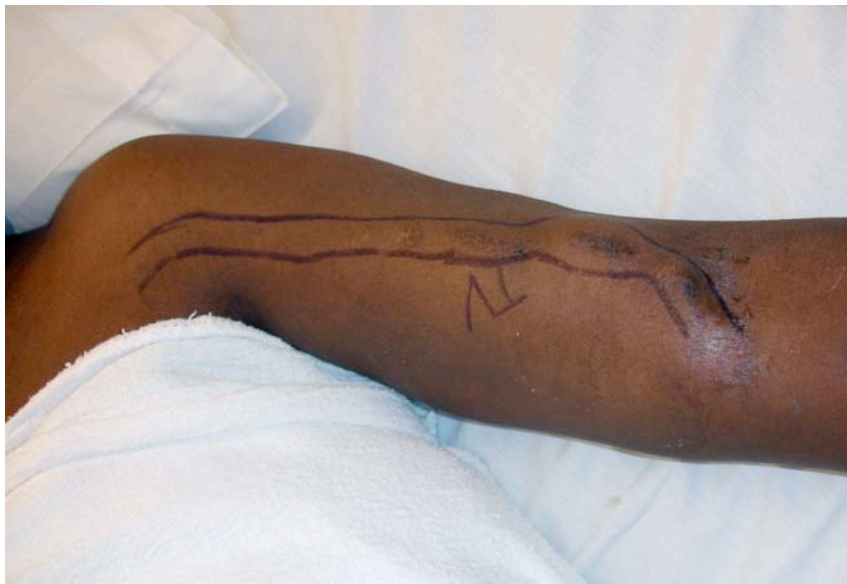A fistulogram highlighting proximal forearm AV fistula. Gracz et al in 1977 described the proximal forearm arteriovenous fistula involving an end-to-side anastomosis between a perforating branch of the cephalic or median antecubital vein and the proximal radial artery. Subsequently several modifications have been described by Bender et al and Kroner et al creating a native fistula utilizing the deep venous system in the forearm and either the proximal radial or brachial artery. The proximal forearm fistula is a valuable additional site for native vascular access for hemodialysis before considering an upper arm access.





Transposed Basilic Vein AVF

A normal transposed basilioc vein arteriovenous fistula showing the scar extending from the axilla to the elbow on the medial aspect of the upper arm.

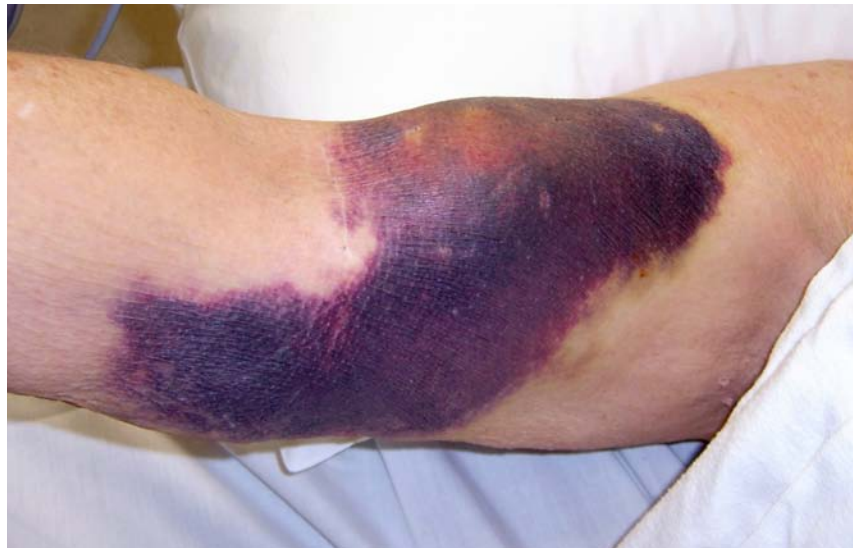
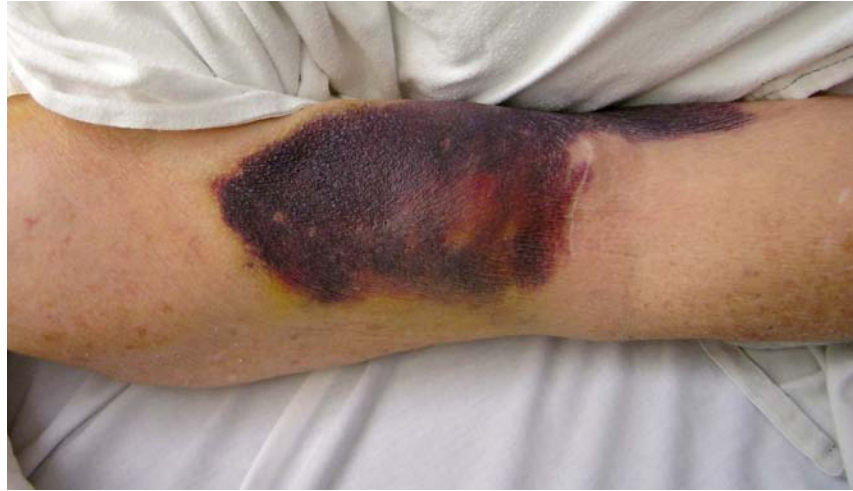
Brachiocephalic AVF

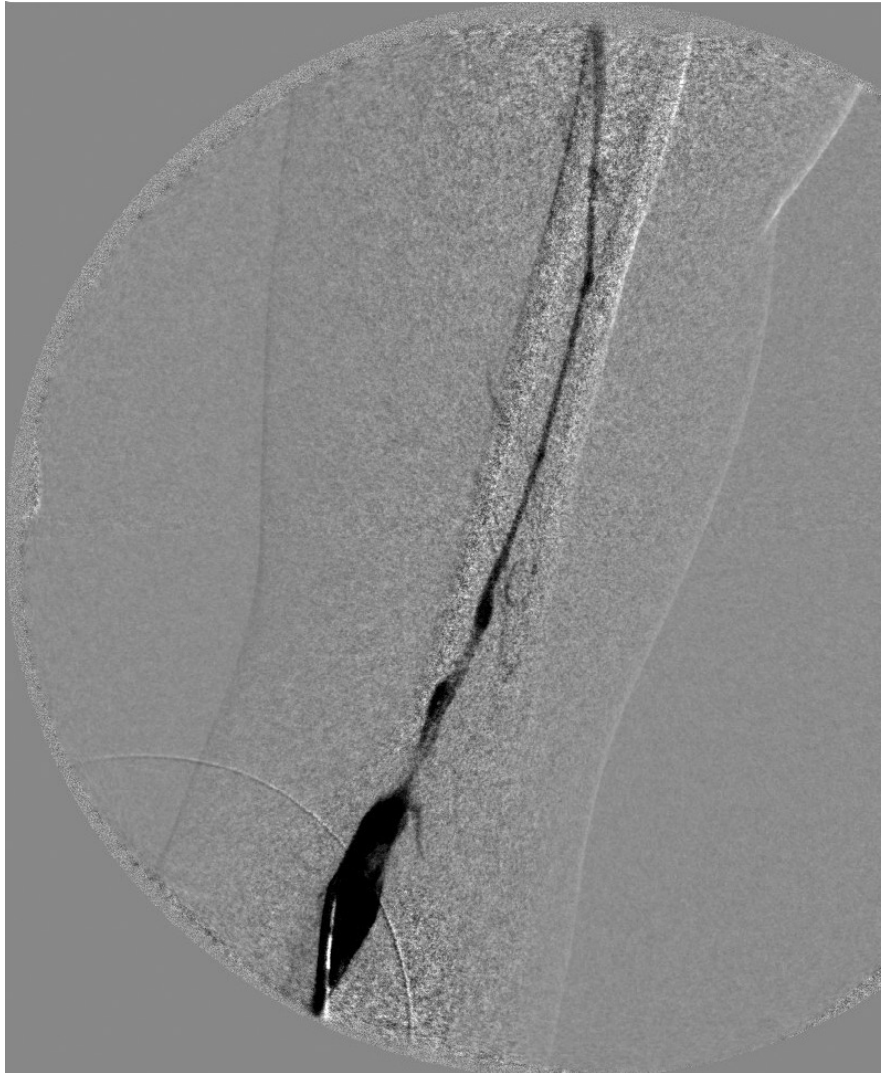A normal brachiocephalic fistula with a horizontal scar at the elbow.

Massive Infiltration

Eighty-year-old patient who had a functioning right brachiocephalic fistula placed well before the need for dialysis. Unfortunately during his first treatment the fistula infiltrated due to improper cannulation technique resulting in a large hematoma almost encircling his upper arm. Fortunately for the patient the fistula was still functional and after 4 weeks of rest to the arm the hematoma resolved completely and the access could be used for dialysis.

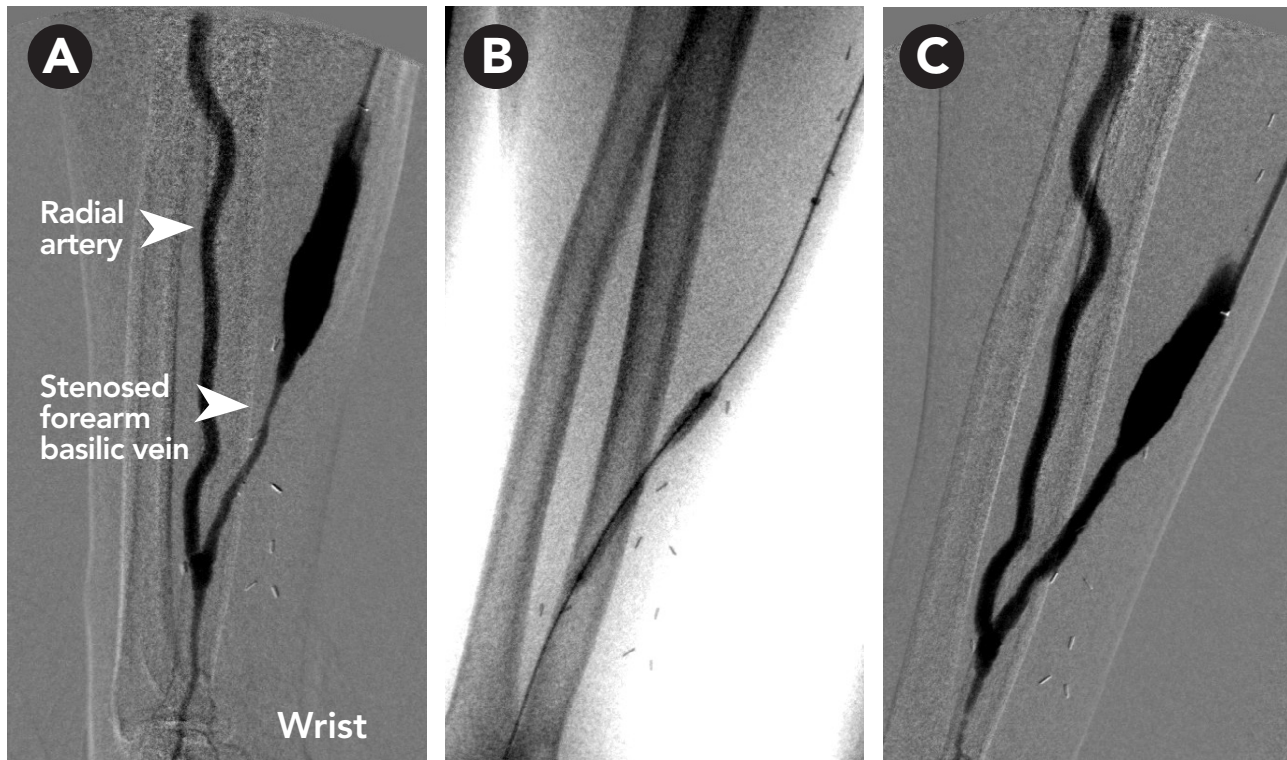


Complication of PICC Line



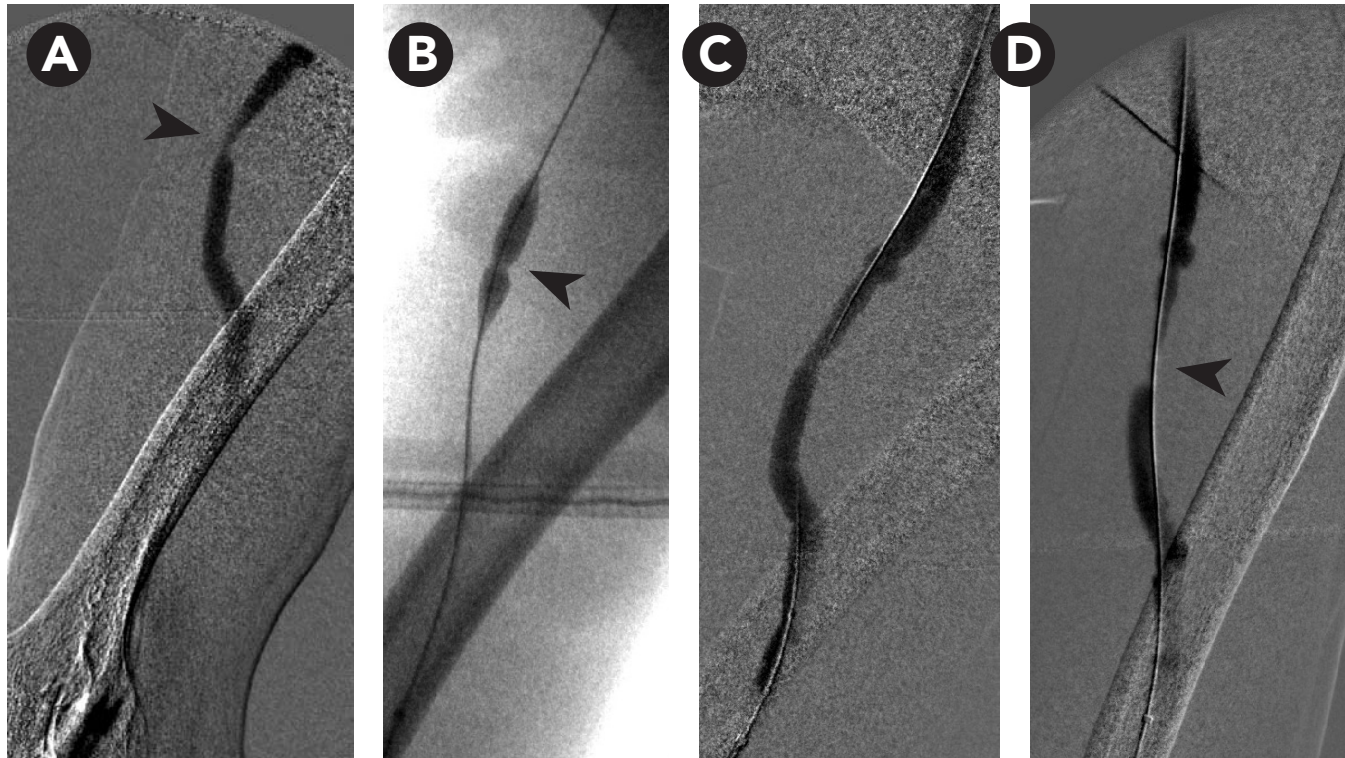
A fistulogram performed on a non-maturing brachiocephalic fistula. The entire cephalic vein segment in the upper arm was small and sclerosed secondary to a previous placement of a peripherally introduced central catheter (PICC). The devastating results of a PICC line can be clearly appreciated in this case.

"Swing site" Stenosis



The fistulogram showing a long inflow segment stenosis which was successfully balloon angioplastied. **A:** Pre-angioplasty. **B:** Waist on the balloon. **C:** Post-angioplasty image.

Thirty-five-year-old patient with a forearm basilic vein to radial artery fistula. The forearm basilic vein was mobilized surgically leading to significant stenosis in the "swing site." The patient presented with inability to achieve prescribed blood flows during dialysis and with high dialysis arterial pressures. On physical examination the inflow augmentation was poor with a very weak pulse and bruit.

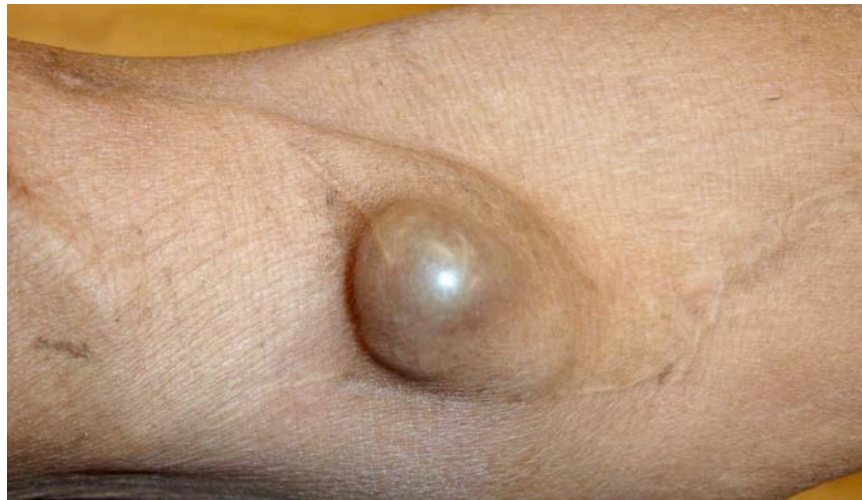
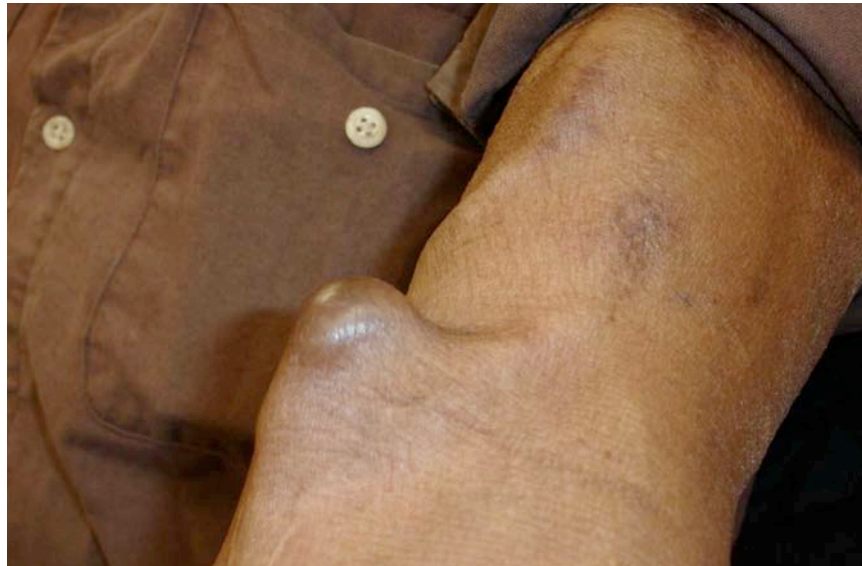
A: Transposed basilic vein AVF with a tight stenosis at the “swing site” (arrowhead). **B:** Waist on the balloon shown during percutaneous angioplasty. **C:** Complete resolution of the stenosis. **D:** Recurrence of the stenosis 4 months later.

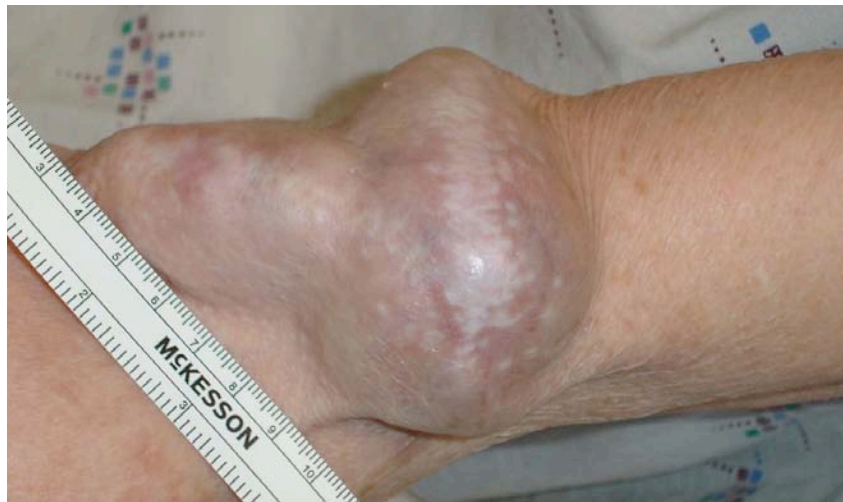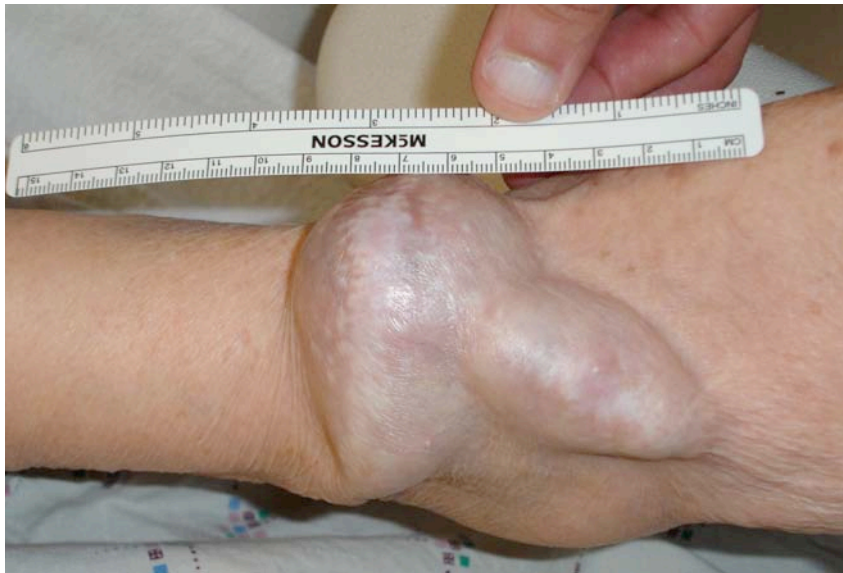A “swing site” stenosis typically presents as a highly pulsatile fistula with a high pitched bruit on physical examination. The dialysis venous pressures are recorded to be high and often the patient continues to bleed for a prolonged period of time once the needle is withdrawn post dialysis therapy.

Aneurysm

Brachiocephalic fistula with an aneurysm at the arterial anastomotic site. The aneurysm has a tight, shiny skin. The patient needs to be referred for an urgent surgical evaluation before a catastrophic event occurs.



Mushroom-shaped Aneurysm



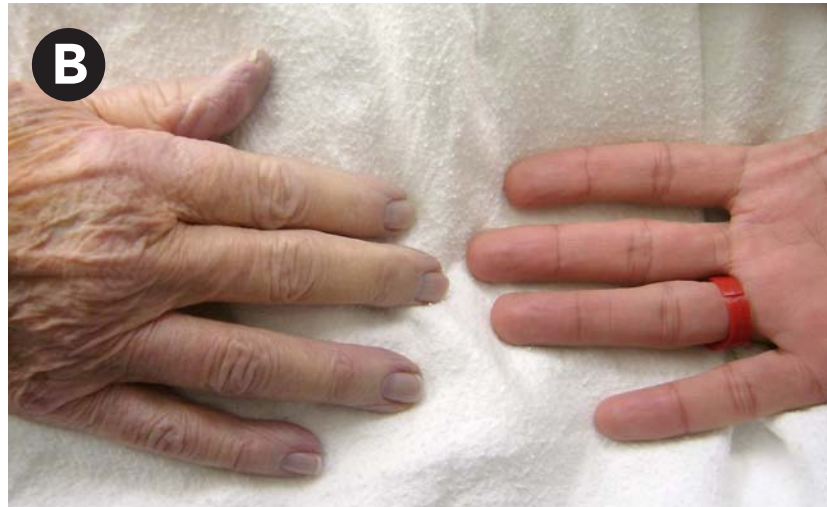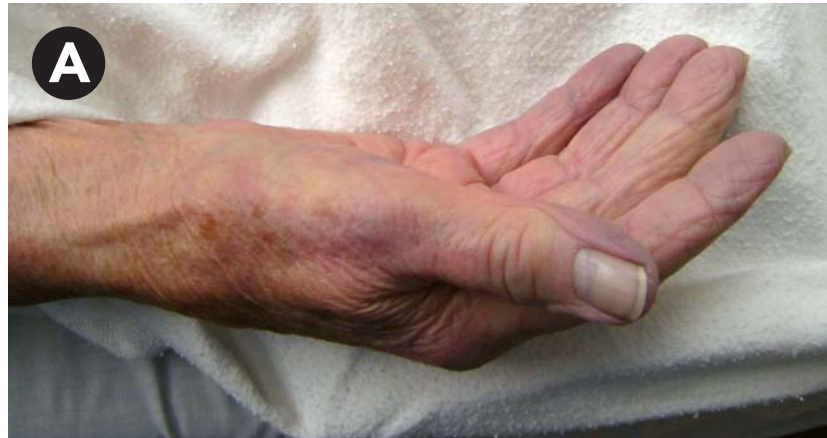86-year-old female with a large "mushroom"-shaped aneurysm at the anastomosis in a brachiocephalic fistula. The aneurysm measures approximately 8cm x 6cm with a shiny and tense-appearing superficial skin.

An aneurysm needs to be monitored on a regular basis to avoid reaching a size as seen in this patient. As per K/DOQI guidelines the patient with an aneurysm 1.5 to 2 times the native vein should be referred for surgical evaluation and monitored at frequent intervals for any changes.

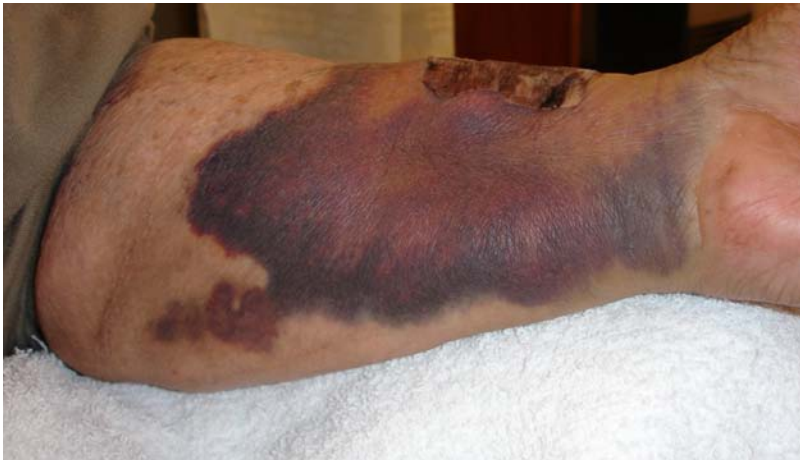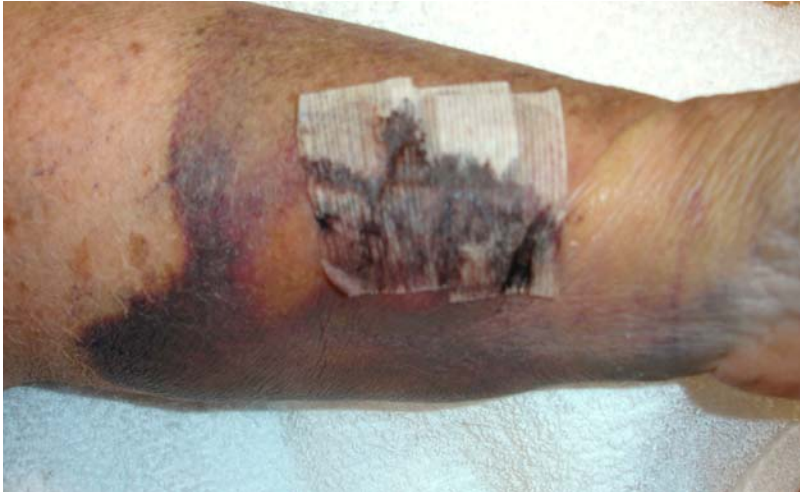Steal syndrome

87-year-old female with a brachiocephalic fistula created approximately 9 months prior to photograph who complained of pain and numbness over her right hand during dialysis. On examination the fingers were blue and cold (**A**). Panel **B** compares the color of her hand to a normal pink color.

Upper arm fistulae are more likely to cause ischemic symptoms compared to forearm fistulae. The presence of poor peripheral vasculature secondary to diabetes, calcification and peripheral arterial disease is the primary etiological factor. A salvage surgical procedure can sometimes be attempted. This patient had extensive peripheral arterial disease requiring ligation of the fistula to preserve distal circulation.



Hematoma

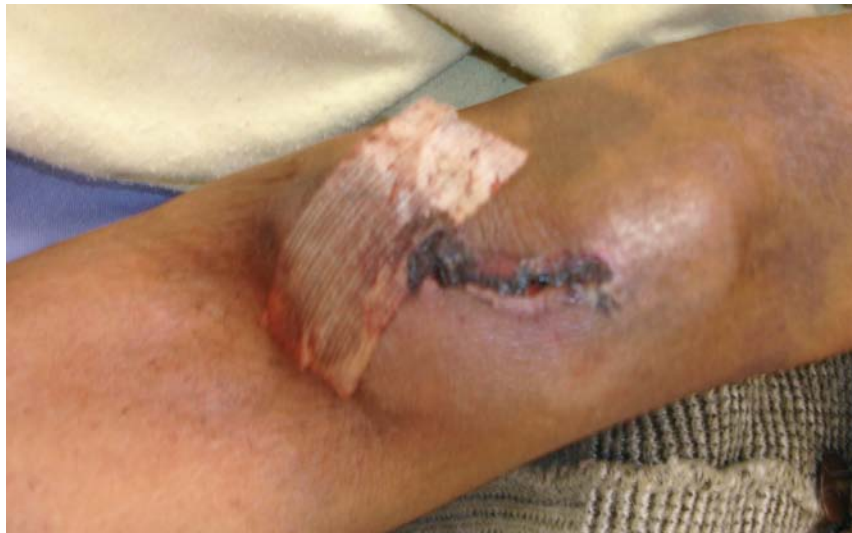
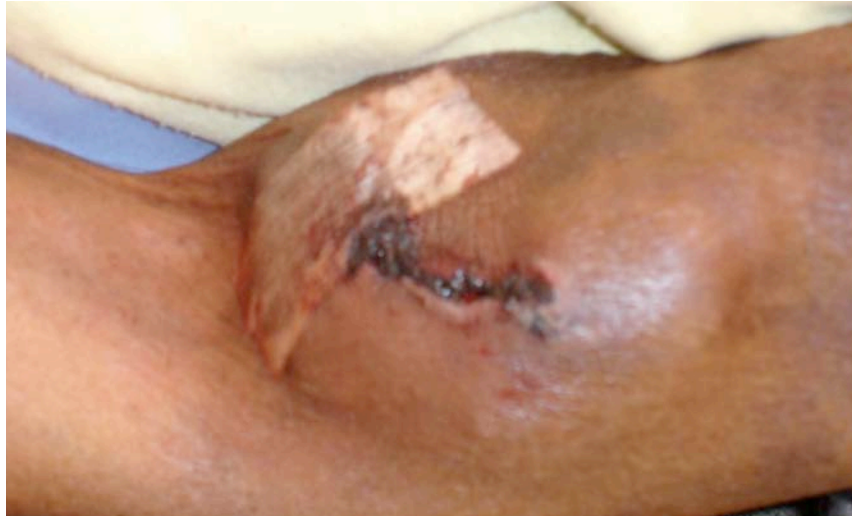
61-year-old female with a recently placed left radiocephalic fistula, developed a large hematoma seven days after the surgery. Patients with chronic kidney disease have an increased tendency to bleed, especially if they are taking additional anti-platelet agents such as aspirin or clopidrogel or are being anti-coagulated with warfarin.

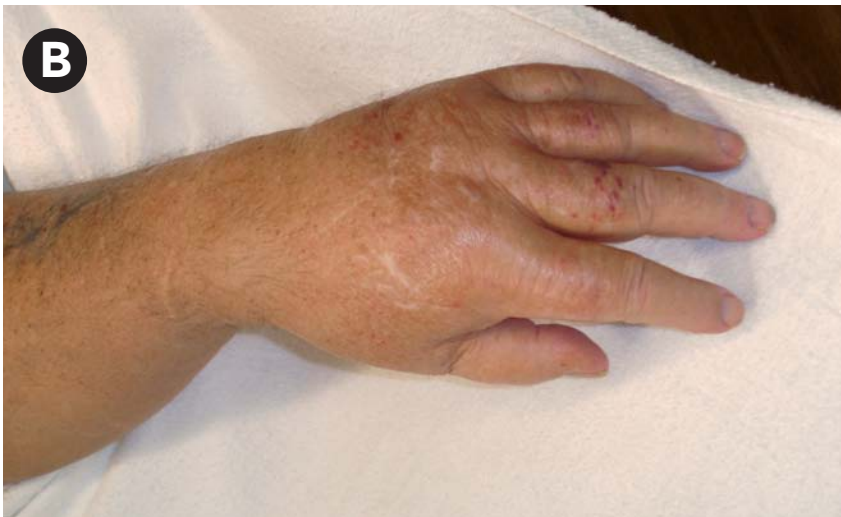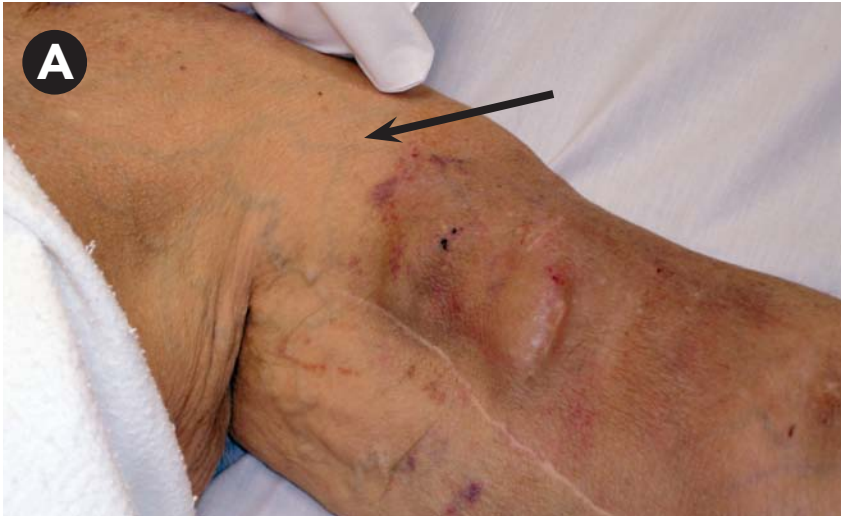Development of a large hematoma and easy bruising is frequently observed in the dialysis population.

Hematoma

73-year-old female patient with a recent surgical revision of brachiocephalic fistula presented with an acute golf ball sized hematoma and a slow leaking pseudoaneurysm. The steristrips were partially supporting the gaping surgical wound. The patient was referred to the vascular surgeon for emergent ligation.



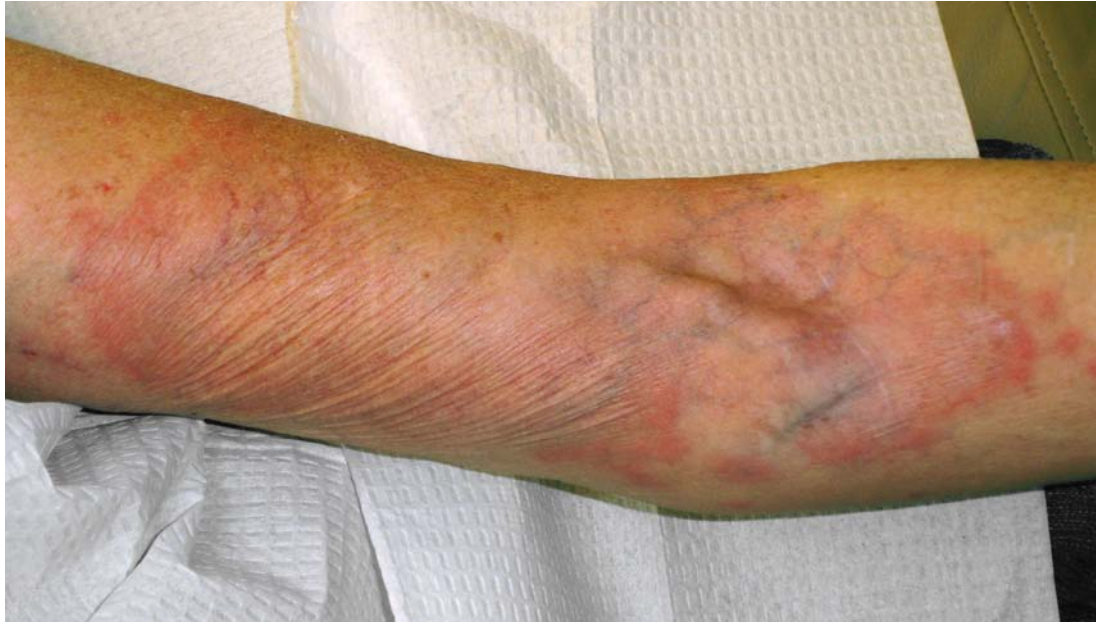Central Vein Stenosis



Sixty-seven-year-old man who presented with left upper arm swelling. He had a transposed basilic vein fistula placed about 18 months prior to photograph. He also had a history of several central venous catheters. On examination, he had prominent collateral veins on his shoulder and chest wall (Panel **A**). The forearm and hand were swollen significantly (**B**).

A fistulogram revealed a 70% stenosis at the “swing site” and 80% stenosis in the left subclavian vein accounting for the collateral veins on the chest wall. The patient was treated successfully with percutaneous angioplasty.

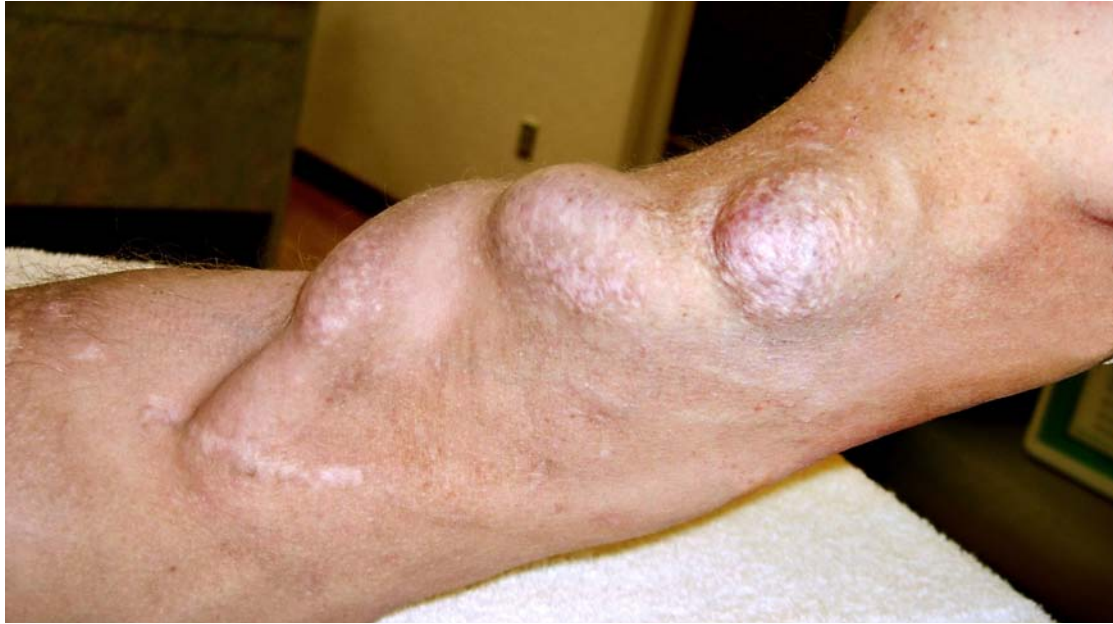Skin Rash



45-year-old male who recently started hemodialysis developed an allergic reaction to betadine. The rash as seen above was erythematous and maculo-papular in nature. The patient complained of severe itching and required therapy with anti-histaminic medications.

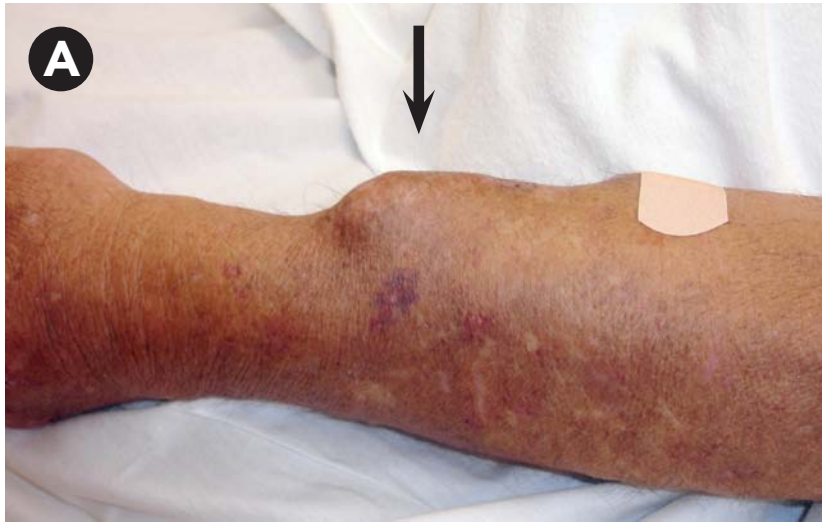Allergic reaction to betadine, iodine, antibiotic cream and tape are not uncommon and need to be well documented in the patient's chart for future reference.

Stable Aneurysm



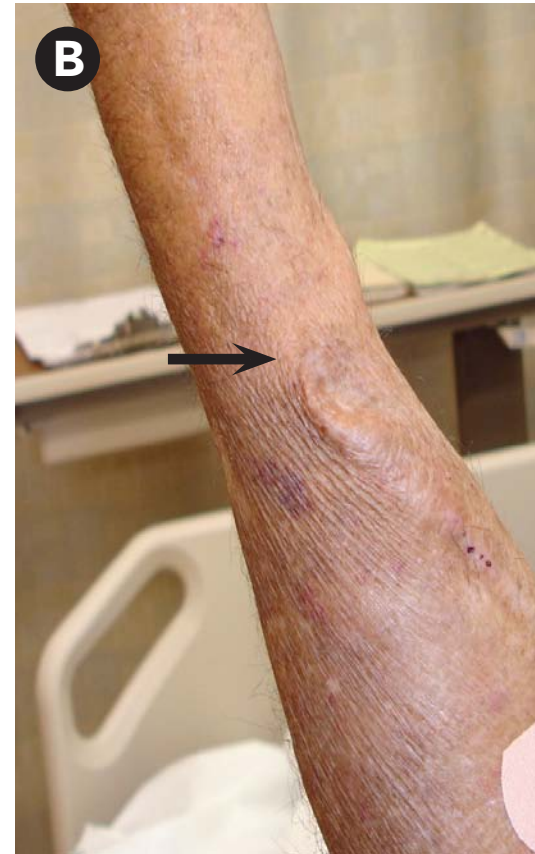36-year-old man with a right brachiocephalic fistula created in 2004. The fistula has several small aneurysms which have been stable. The overlying skin is intact without any change in pigmentation. The fistula did not have any evidence of outflow obstruction on physical examination. A central vein stenosis was ruled out on fistulogram. The fistula needs to be monitored and patient was educated to inform about any increase in size or skin changes. The fistula size should be measured and documented in the medical records for future reference.

Arm Elevation Test

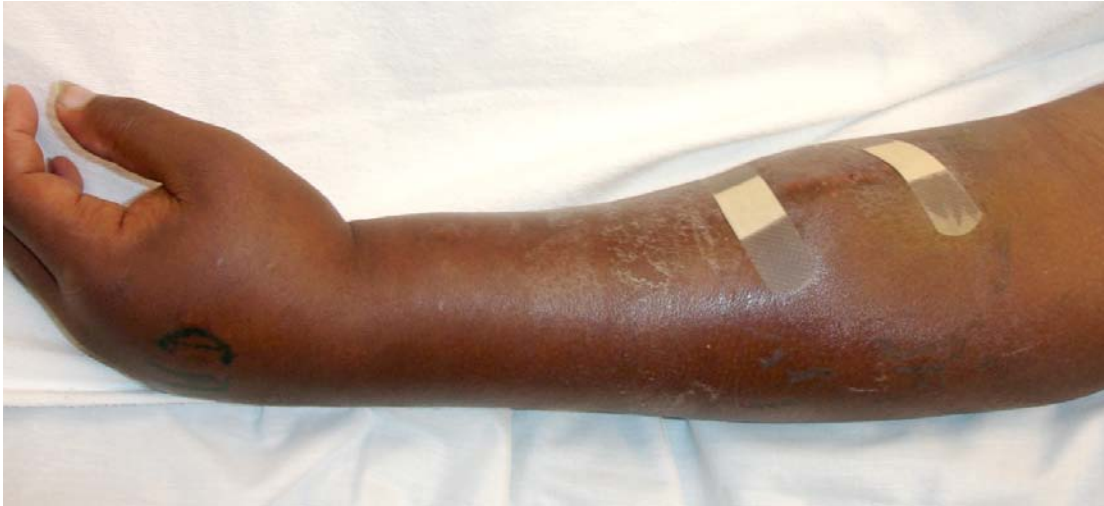

Seventy-four-year-old male with a radiocephalic fistula created in 2007. Panel **A** shows the fullness (arrow) near the anastomosis due a small aneurysm.

The fullness collapses completely on arm elevation (Panel **B**, arrow) suggesting an absence of significant outflow obstruction. A simple bedside examination that needs to be performed prior to every dialysis session.



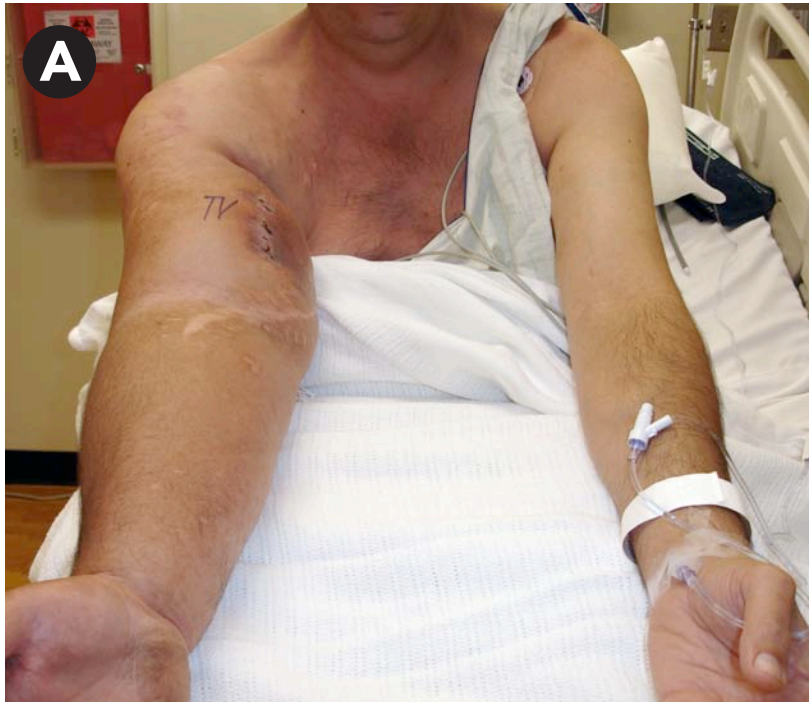Red Hand Syndrome



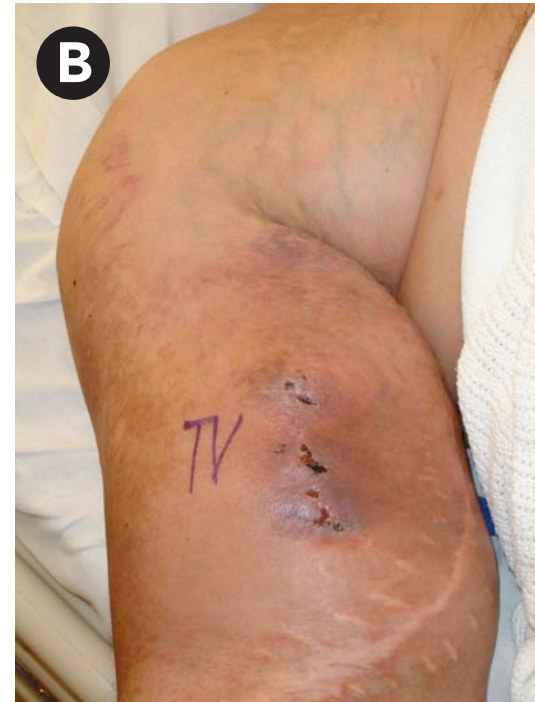Twenty-four-year-old male with a radiocephalic fistula that was created in 2007. The patient presented after having noticed increased swelling, warmth and difficulty cannulating during dialysis. On examination the forearm and hand were swollen and erythematous. A bruit was heard distal to the fistula. The patient was treated with antibiotics for cellulitis. The arm remained swollen even after the resolution of cellulitis.

A fistulogram revealed multiple collateral veins without any significant outflow stenosis with increased distal blood flow causing "red hand" syndrome from venous stasis. The patient was sent for surgical ligation of multiple collateral veins, which resulted in complete resolution of his symptoms. The fistula was salvaged.

Central Vein Stenosis



A: Massively swollen right upper extremity from completely occluded right subclavian vein. The transposed basilic vein arteriovenous fistula is patent.



B: Extensive network of collateral veins over the right shoulder and chest area.

ARTERIOVENOUS GRAFTS

Arteriovenous grafts (AVG) are used for patients who do not have adequate native veins for creating a fistula. An AVG is the second best option for hemodialysis.

Several sites are used for AVG placement. Forearm loop AVG is the most common. Upper arm grafts are generally placed as a straight connection between the brachial artery and the basilic or axillary vein. A thigh AVG is generally a last resort when all other options in the upper torso are unavailable due to variety of reasons.

AVG are rarely placed across the chest wall, connecting the axillary artery and axillary vein or axillary artery and a suitable vein on the opposite site. AVG have also been rarely connected to the right atrial appendage.

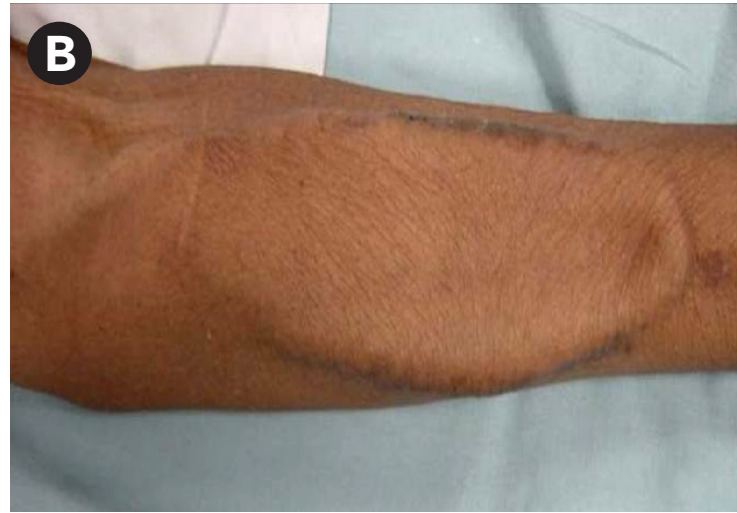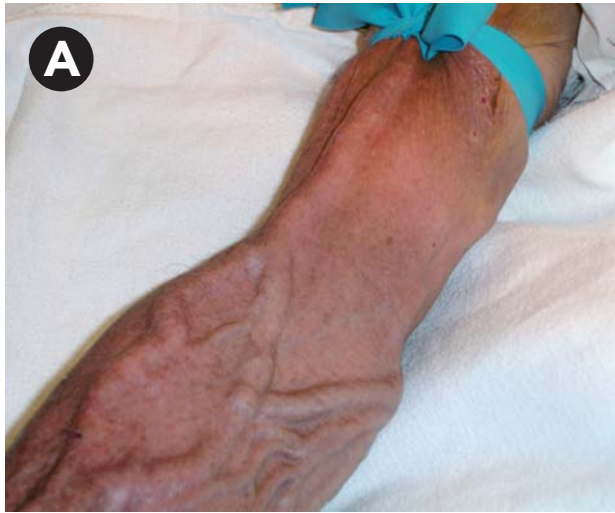The common problems associated with an AVG are:

- Venous anastomotic stenosis from neo-intimal hyperplasia
- Development of pseudoaneurysms
- Thrombosis
- Infection
- Central vein stenosis, especially with history of multiple central venous catheters

Using a tourniquet is not required while cannulating a graft but it is **absolutely** essential for an AVF.

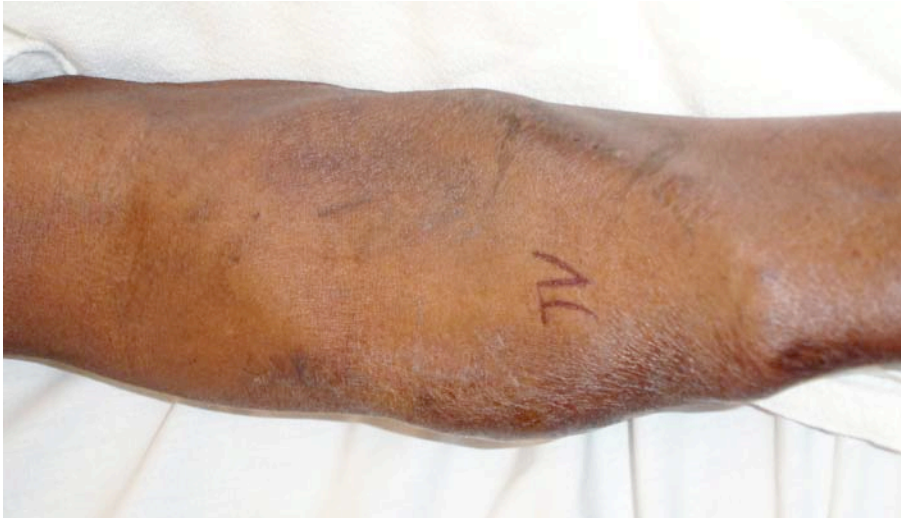The current chapter highlights some of the common problems associated with an AVG.

Tourniquet Use



Using a tourniquet is an absolute must for an arteriovenous fistula (Panel **A**), which is not required for an arteriovenous graft (**B**).

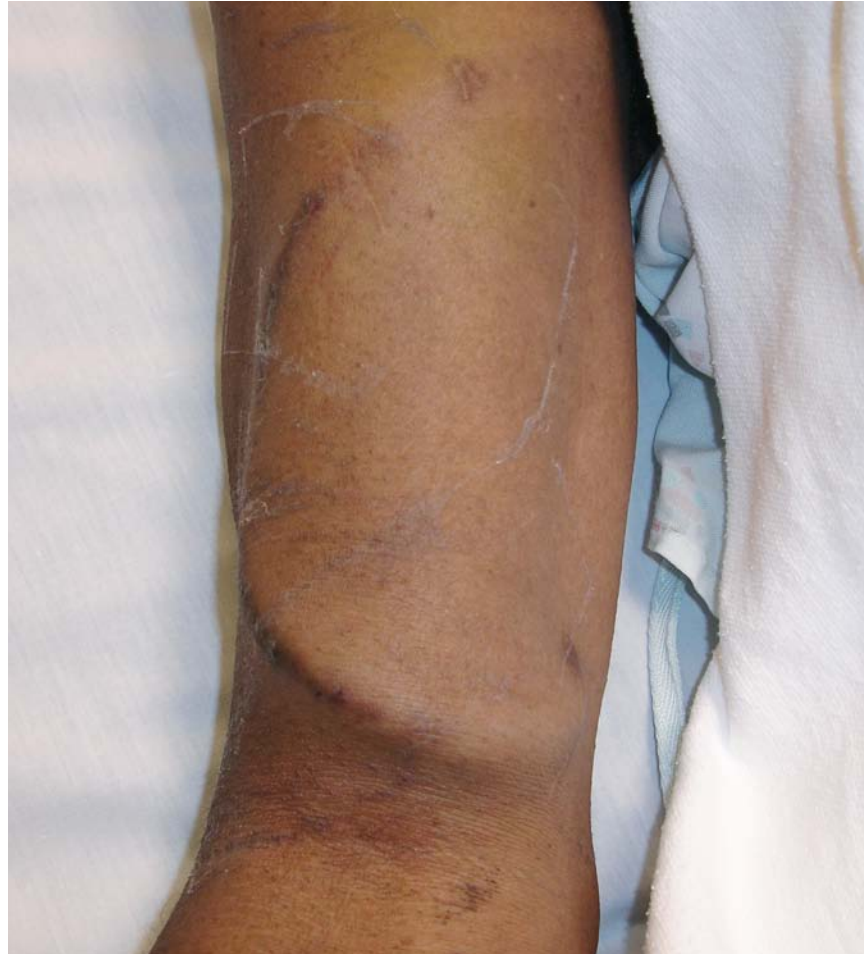Forearm Loop Arteriovenous Graft



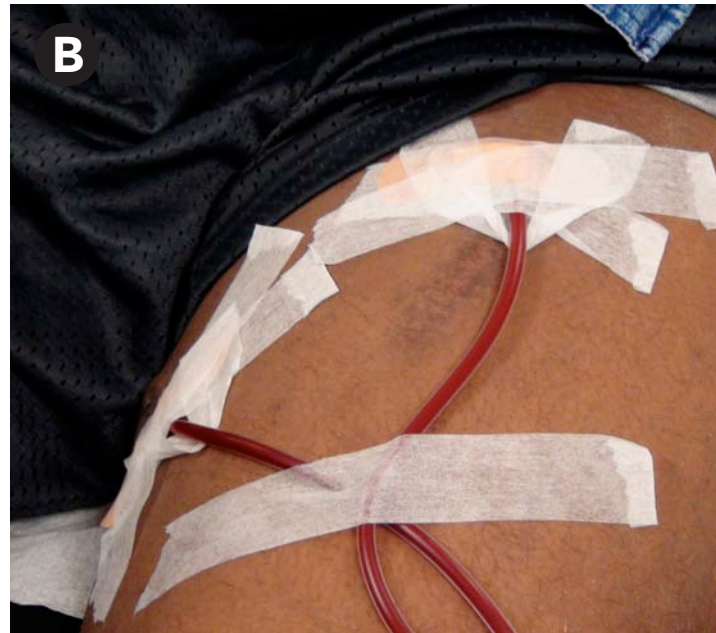
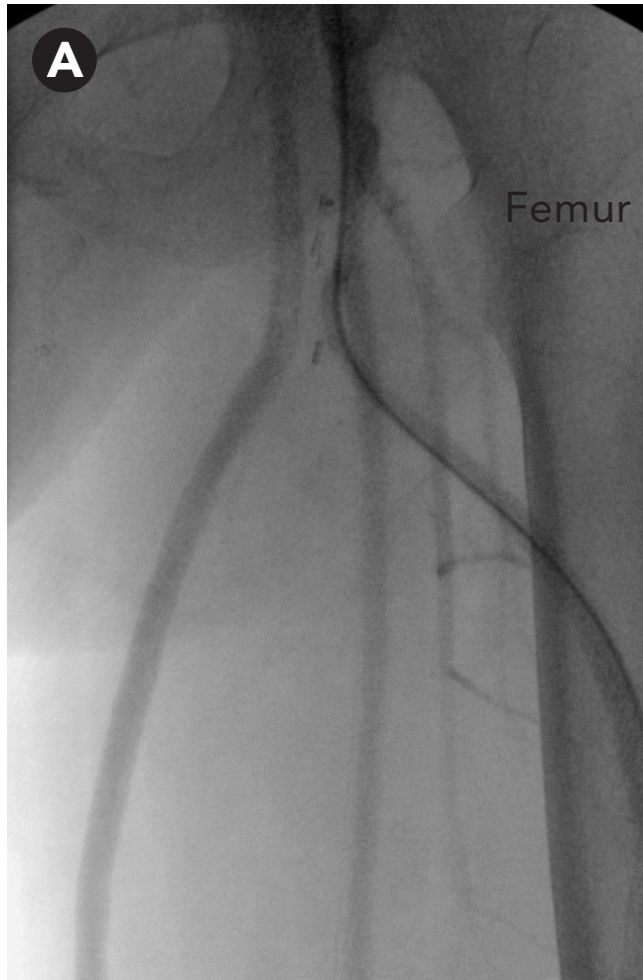
A normal forearm loop arteriovenous graft.

Upper Arm AVG

A normal upper arm arteriovenous graft.



Thigh AVG



- A.** Arteriogram showing the patent arteriovenous graft in the thigh.
- B.** A normal thigh arteriovenous graft being used for dialysis.

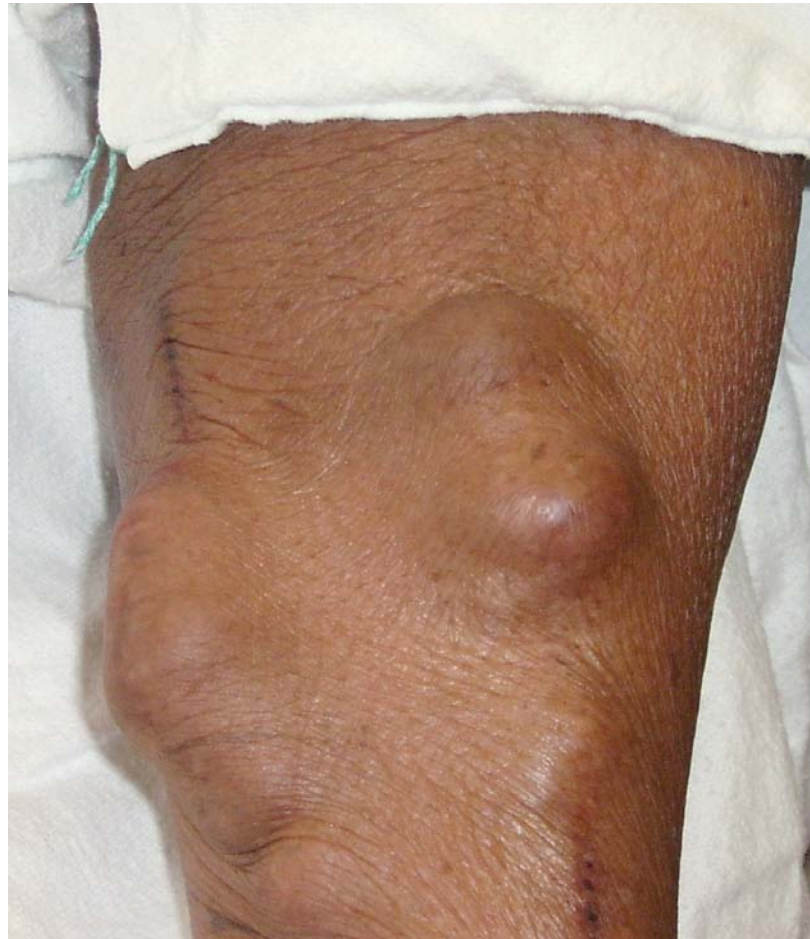Photo courtesy of Jack Work, MD

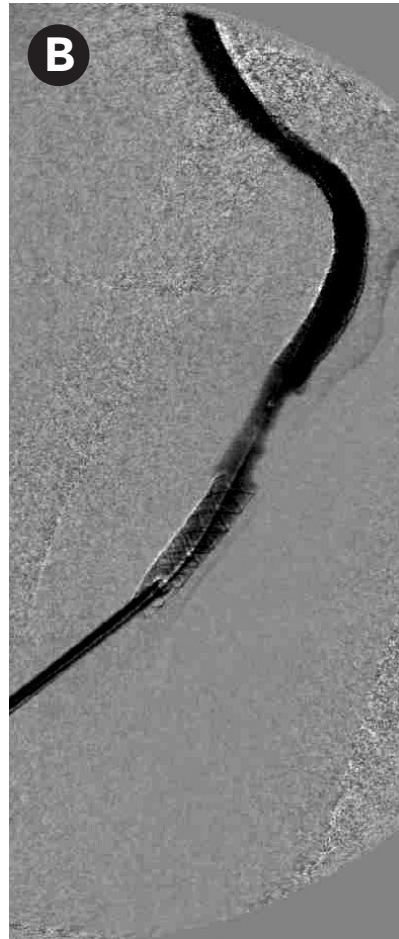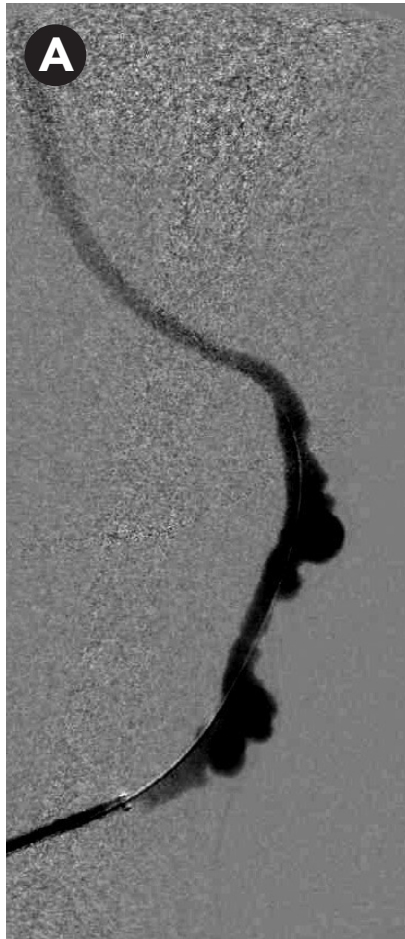
Pseudoaneurysm

Development of pseudoaneurysms over time in an arteriovenous graft is not uncommon. The pseudoaneurysms develop at frequently punctured sites and may worsen in the presence of proximal stenosis.

The needle puncture sites should be rotated to minimize this complication. Smaller pseudoaneurysms can be treated endovascularly with a covered stent as long as it does not compromise the cannulation segment, as shown in the next image. Larger pseudoaneurysms need to be treated surgically.

Pseudoaneurysms tend to develop clots and can lead to thrombosis of the access. The risk of bleeding is higher if the pseudoaneurysm is cannulated for dialysis.



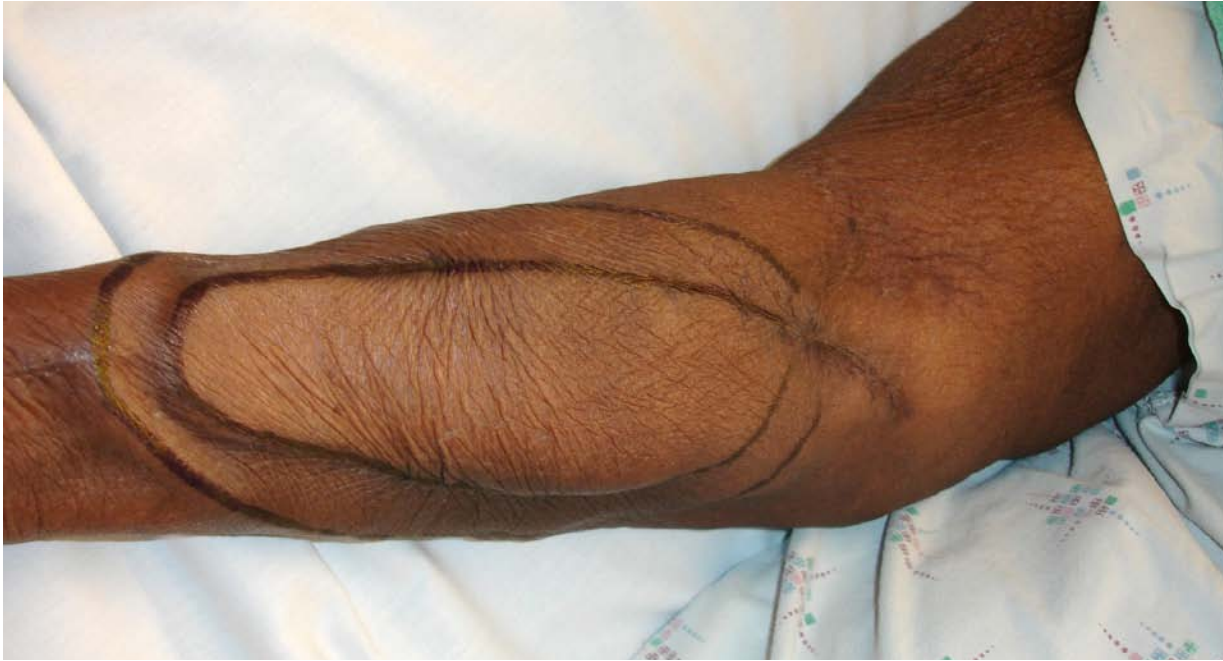

Smaller pseudoaneurysms with superficial skin changes can be at an increased risk of rupture and bleeding. Panel **A** shows multiple pseudoaneurysms in a patient with significant skin changes. Due to multiple medical problems she was a high risk for surgical intervention and hence an endovascular procedure was performed.

Patient underwent an endovascular procedure involving a deployment of a covered stent (**B**) resulting in salvaging the graft and preventing the pseudoaneurysms from expanding further.

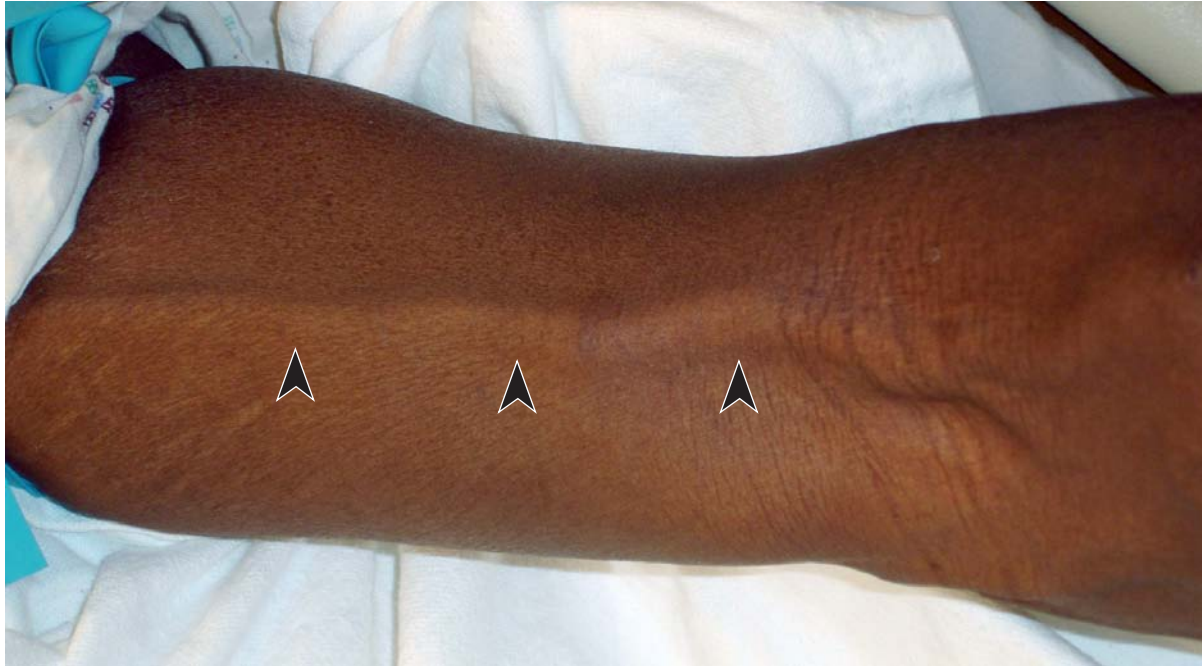A covered stent is a stent coated with PTFE-like material making it suitable for cannulation during dialysis, if absolutely necessary.

Multiple Arteriovenous Grafts



Eighty-six-year-old female with a failed forearm loop AVG (inner loop). A new AVG was placed successfully, utilizing the same arterial inflow and venous outflow anastomosis (outer loop). Using a long forearm loop of PTFE can increase the risk of thrombosis due to increased resistance, but fortunately this patient has had a functioning access one year after surgery.

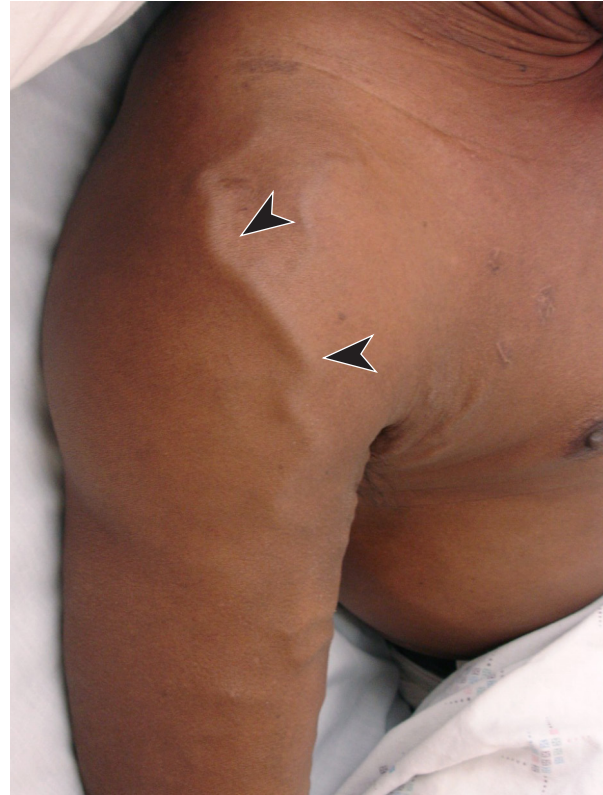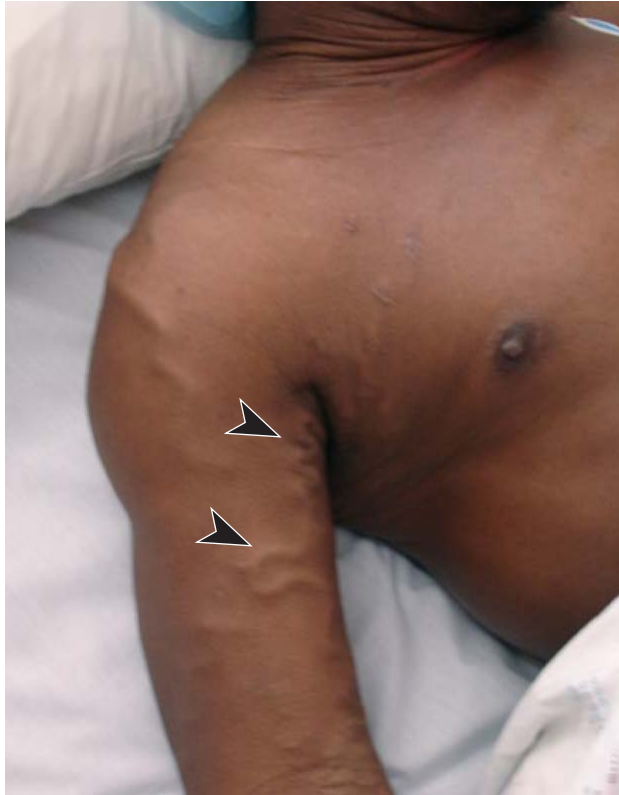“Sleeves Up” Examination



“Sleeves Up” Examination for every AVG:

All patients with forearm AVGs should have a routine “sleeves up” examination of the upper arm as seen in this patient. The upper arm cephalic vein (arrow heads) is nicely developed and can be utilized for future conversion to a secondary arterio-venous fistula.

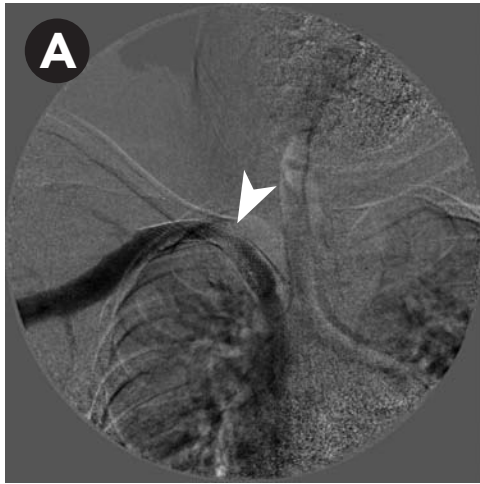
Central Vein Stenosis



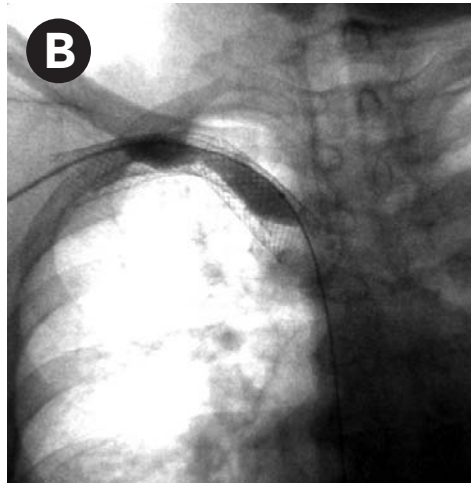
Forty-five-year-old male with a right forearm loop AVG placed in 2003 has marked central vein stenosis. The collateral veins are visualized on his shoulder and chest (arrowheads).

The patient has a right subclavian vein stent with recurrent stenosis as shown in next image.

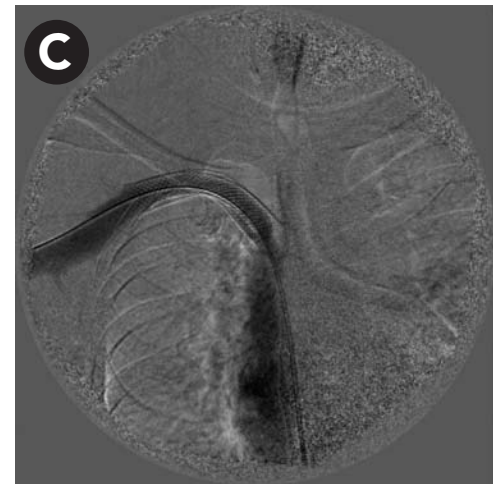
Central Venogram



A: Intrastent stenosis (arrowhead) in the right subclavian vein.

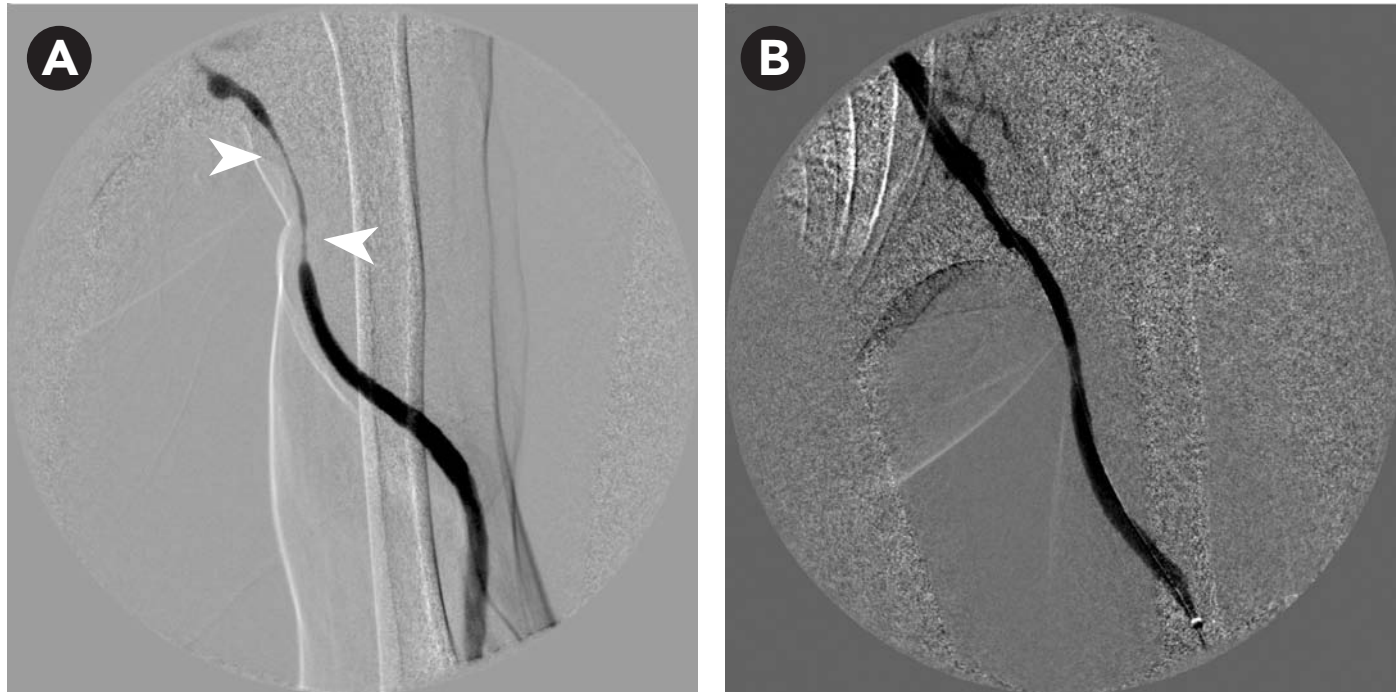

B: Waist on the balloon used for angioplasty.



C: Post-angioplasty complete resolution of the stenosis.

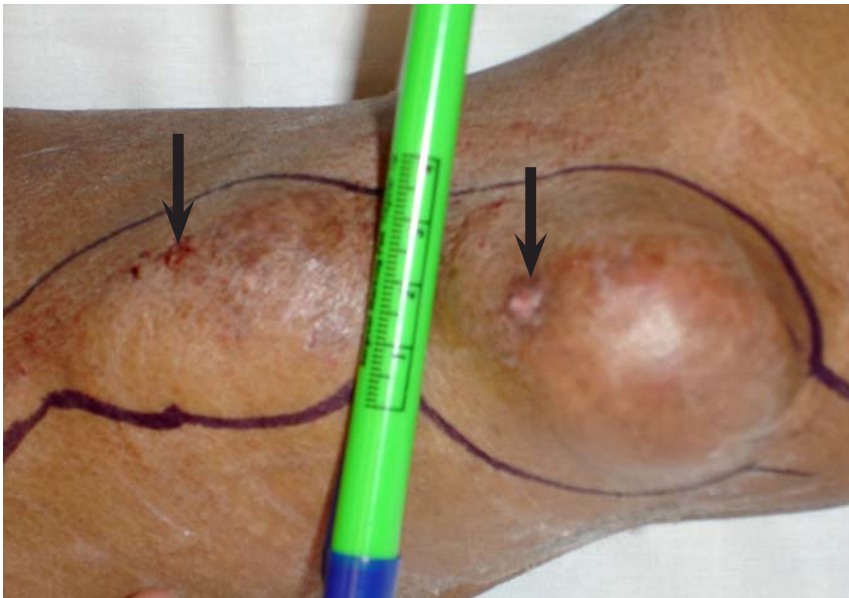
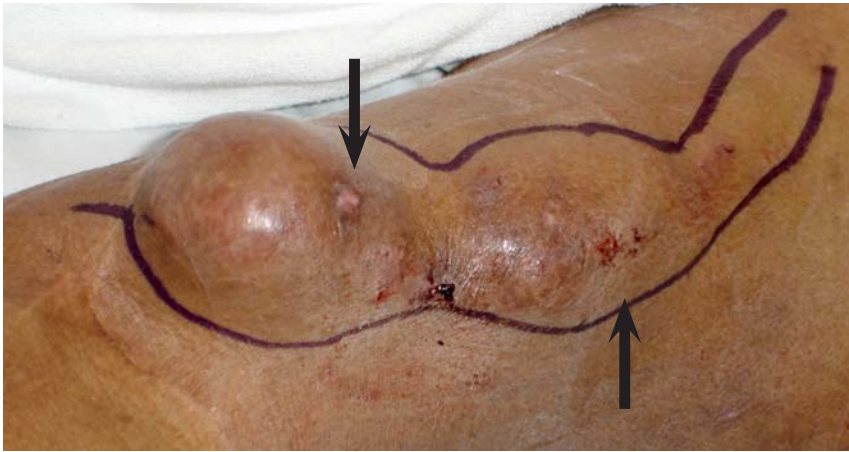
Venous Outflow Stenosis



Ninety-three-year-old male with a left upper arm straight AVG with classic venous outflow stenosis. The patient was referred for a fistulogram based on clinical findings of pulsatile character to AVG and prolonged bleeding (more than 30 min.) following dialysis needle withdrawal.

An 8cm long segment of stenosis extending from the graft in to the axillary vein was noted on fistulogram (arrowheads in Panel **A**). The stenosis was successfully angioplastied using an 8mm balloon without any residual stenosis (**B**).

Pseudoaneurysm

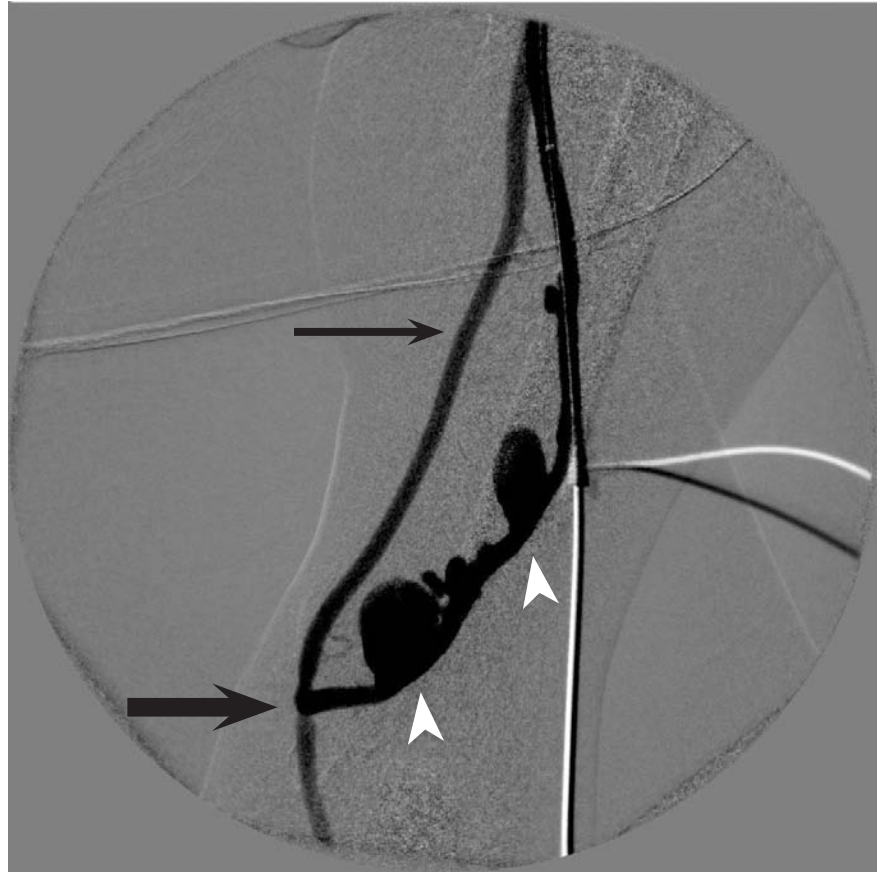

65-year-old female patient presented with left upper arm AVG with large pseudoaneurysms measuring 4cm in diameter. The aneurysms are close to the arterial anastomosis and were being frequently punctured for dialysis cannulation (arrows).

The AVG in the upper extremity has a lumen diameter of 0.6cm. The current recommendation from K/DOQI is to refer patients for surgical evaluation if the diameter is 1.5-2 times the normal, i.e. 1.2-1.5 cm.

Pseudoaneurysm

A fistulogram of a left upper arm AVG is shown. The brachial artery (thin black arrow) is smooth with a widely patent arterial anastomosis (thick black arrow). The AVG has multiple pseudoaneurysms (white arrow heads) that are large and at frequently punctured sites. A surgical revision of the graft would be the best available option.



Glossary

AVF – Arteriovenous fistula

AVG – Arteriovenous graft

CVC – Central venous catheter

TCC – Tunneled cuffed catheter (same as CVC)

Fistulogram – A radiological test performed using an iodinated radiocontrast material to evaluate the access

PTA – Percutaneous transluminal angioplasty or balloon angioplasty

PTFE – Polytetrafluoroethylene graft, the synthetic material used for AVG

tPA – Tissue plasminogen activator a thrombolytic agent used for clot lysis

Terminologies used for a central vein catheter:

Venotomy site - The site where the catheter enters the vein

Exit site – Site where the catheter exits from the skin

Tunnel – The subcutaneous section of the catheter between the venotomy and exit sites

Butterfly – The wing beyond the exit site on the catheter used for anchoring the catheter to the skin

Terminologies used for dialysis access examination:

Inflow or **upstream** – indicates the arterial side of the access

Outflow or **downstream** – indicates the venous side of the access all the way to the right atrium

Arterial anastomosis – Point where the native vein is surgically connected to the feeding artery or where the PTFE is connected to the artery

Venous anastomosis – Native fistulae do not have a venous anastomosis. The AVG connection to the outflow vein is called venous anastomosis

Proximal – Anything towards the heart from a reference point

Distal – Anything away from the heart from a reference point

Bifurcation – Forking of a vein or an artery

Collateral veins – Accessory veins that are prominent and may prevent maturation of the fistula

Reference

- Badero OJ, Salifu MO, Wasse H, Work J. Frequency of swing-segment stenosis in referred dialysis patients with angiographically documented lesions. *Am J Kidney Dis.* 2008;51:93-8.
- Balaz P, Rokosny S, Klein D, Adamec M. Aneurysmorrhaphy is an easy technique for arteriovenous fistula salvage. *J Vasc Access.* 2008;9:81-4.
- Barshes NR, Annambhotla S, Bechara C, et al. Endovascular repair of hemodialysis graft-related pseudoaneurysm: an alternative treatment strategy in salvaging failing dialysis access. *Vasc Endovascular Surg.* 2008;42:228-34.
- Beathard GA. Catheter thrombosis. *Semin Dial.* 2001;14:441-5.
- Bender MH, Bruyninck CM, Gerlag P. The Gracz arteriovenous fistula evaluated: Results of the brachiocephalic elbow fistula in haemodialysis angio-access. *Eur J Vasc Endovasc Surg* 10. 1995;294-297
- Berman SS, Gentile AT, Glickman MH, et al. Distal revascularization-interval ligation for limb salvage and maintenance of dialysis access in ischemic steal syndrome. *J Vasc Surg.* 1997;26:393-402; discussion 402-4.
- Bourquelot P, Gaudric J, Turmel-Rodrigues L, Franco G, Van Laere O, Raynaud A. Transposition of radial artery for reduction of excessive high-flow in autogenous arm accesses for hemodialysis. *J Vasc Surg.* 2009;49:424-8, 428 e1.
- Cavallaro G, Taranto F, Cavallaro E, Quatra F. Vascular complications of native arteriovenous fistulas for hemodialysis: role of microsurgery. *Microsurgery.* 2000;20:252-4.
- Clark TW, Cohen RA, Kwak A, Markmann JF, Stavropoulos SW, Patel AA, Soulen MC, Mondschein JI, Kobrin S, Shlansky-Goldberg RD, Trerotola SO. Salvage of non-maturing native fistulas by using angioplasty. *Radiology.* 2007;242:286-92.
- Faintuch S, Salazar GM. Malfunction of dialysis catheters: management of fibrin sheath and related problems. *Tech Vasc Interv Radiol.* 2008;11:195-200.
- Gracz KC, Ing TS, Soung LS, Armbruster KF, Seim SK, Merkel FK. Proximal forearm fistula for maintenance hemodialysis. *Kidney Int.* 1977;11(1):71-5.
- Hausegger KA, Tiessenhausen K, Klimpfinger M, Raith J, Hauser H, Tauss J. Aneurysms of hemodialysis access grafts: treatment with covered stents: a report of three cases. *Cardiovasc Intervent Radiol.* 1998; 21:334-7.
- Janne d'Othee B, Tham JC, Sheiman RG. Restoration of patency in failing tunneled hemodialysis catheters: a comparison of catheter exchange, exchange and balloon disruption of the fibrin sheath, and femoral stripping. *J Vasc Interv Radiol.* 2006;17:1011-5.
- Keeling AN, Naughton PA, McGrath FP, Conlon PJ, Lee MJ. Successful endovascular treatment of a hemodialysis graft pseudoaneurysm by covered stent and direct percutaneous thrombin injection. *Semin Dial.* 2008; 21:553-6.
- Konner K, Hulbert-Shearon TE, Roys EC, Port FK. Tailoring the initial vascular access for dialysis patients. *Kidney Int.* 2002;62:329-338.

- MacRae JM, Pandeya S, Humen DP, Krivitski N, Lindsay RM. Arteriovenous fistula-associated high-output cardiac failure: a review of mechanisms. *Am J Kidney Dis.* 2004;43(5):e17-22.
- Minion DJ, Moore E, Edean E. Revision using distal inflow: a novel approach to dialysis-associated steal syndrome. *Ann Vasc Surg.* 2005;19:625-8.
- Muhm M, Sunder-Plassmann G, Apsner R, et al. Malposition of central venous catheters. Incidence, management and preventive practices. *Wien Klin Wochenschr.* 1997;109:400-5.
- Najibi S, Bush RL, Terramani TT, et al. Covered stent exclusion of dialysis access pseudoaneurysms. *J Surg Res.* 2002;106:15-9.
- Rajan DK, Bunston S, Misra S, Pinto R, Lok CE. Dysfunctional autogenous hemodialysis fistulas: outcomes after angioplasty—are there clinical predictors of patency? *Radiology.* 2004;232:508-15.
- Rajan DK, Clark TW, Patel NK, Stavropoulos SW, Simons ME. Prevalence and treatment of cephalic arch stenosis in dysfunctional autogenous hemodialysis fistulas. *J Vasc Interv Radio.* 2003;14:567-73.
- Rodriguez, HE, Leon, L, Schalch, P, Labropoulos, N, Borge, M, Kalman, PG. Arteriovenous access: managing common problems. *Perspect Vasc Surg Endovasc Ther.* 2005;17:155-66.
- Salik E, Daftary A, Tal MG. Three-dimensional anatomy of the left central veins: implications for dialysis catheter placement. *J Vasc Interv Radiol.* 2007;18(3):361-4.
- Schon D, Whittman D. Managing the complications of long-term tunneled dialysis catheters. *Semin Dial.* 2003;16:314-22.
- Silas AM, Bettmann MA. Utility of covered stents for revision of aging failing synthetic hemodialysis grafts: a report of three cases. *Cardiovasc Intervent Radiol.* 2003;26:550-3.
- Spergel LM, Ravani P, Roy-Chaudhury P, Asif A, Besarab A. Surgical salvage of the auto-genous arteriovenous fistula (AVF). *J Nephrol.* 2007;20:388-98.
- Suojanen JN, Brophy DP, Nasser I. Thrombus on indwelling central venous catheters: the histopathology of “Fibrin sheaths”. *Cardiovasc Intervent Radiol.* 2000;23:194-7.
- Tessitore N, Mansueto G, Lipari G, et al. Endovascular versus surgical preemptive repair of forearm arteriovenous fistula juxta-anastomotic stenosis: analysis of data collected prospectively from 1999 to 2004. *Clin J Am Soc Nephrol.* 2006;1:448-54.
- Vernhet H, Dogas G, Senac J. Dysfunctioning of central venous catheters: role of the radiologist. *Nephrologie.* 2001;22:425-7.
- Wong JK, Sadler DJ, McCarthy M, Saliken JC, So C, Gray RR. Analysis of early failure of tunneled hemodialysis catheters. *AJR Am J Roentgenol.* 2002;179:357-63.